

## Signal Normalization in Surface-Coil MR Imaging

Bernd K. Wallner,<sup>1,2</sup> Robert R. Edelman,<sup>1</sup> Richard L. Bajakian,<sup>1</sup> Jonathan Kleefield,<sup>1</sup> Dennis J. Atkinson,<sup>3</sup> and Heinrich P. Mattle<sup>1,4</sup>

Flat surface coils show signal loss with increasing distance from the coil plane. With standard windowing settings, detail within the subcutaneous fat and other superficial tissues may be obscured. Postprocessing techniques have been previously shown to improve the signal uniformity in surface-coil images [1, 2]. Despite the potential benefits of such methods, intensity correction also has the potential to introduce artifacts into the image or cause a loss of diagnostic information. We therefore performed a blinded study to determine the benefits and drawbacks of image normalization.

### Materials and Methods

A simplified normalization technique was employed. The intensity of each voxel in the image was multiplied by a conversion factor  $F(x,y) = [r(x,y) + b]^a/c$ , where  $r(x,y)$  = distance from the coil center,  $a$  = an exponential factor,  $b$  = a shape factor, and  $c$  = a scaling factor for image brightness. Various values of the exponential factor

$a$ , ranging from 0.5 to 3.0 were tested; empirically, a value of 2.3 was found to be optimal. The shape factor  $b$  determines whether the distribution of signal corrections is more disk-shaped or spherical. For large coils, a large  $b$  value is chosen; for small coils, a lower value is employed. The examinations were performed on a 1.5-T imager (Magnetom, Siemens Erlangen, FRG). The images from 20 consecutive lumbar studies and one orbit study were examined pre- and postnormalization to determine the advantages and drawbacks of the method.

### Results

There was consistent improvement in signal uniformity, which was most evident on T1-weighted and proton-density-weighted images (Fig. 1). This allowed better evaluation of the posterior spinal elements and superficial soft tissues in spine images, and of the deep brain structures in orbit images. Of particular value was the improved ease in windowing

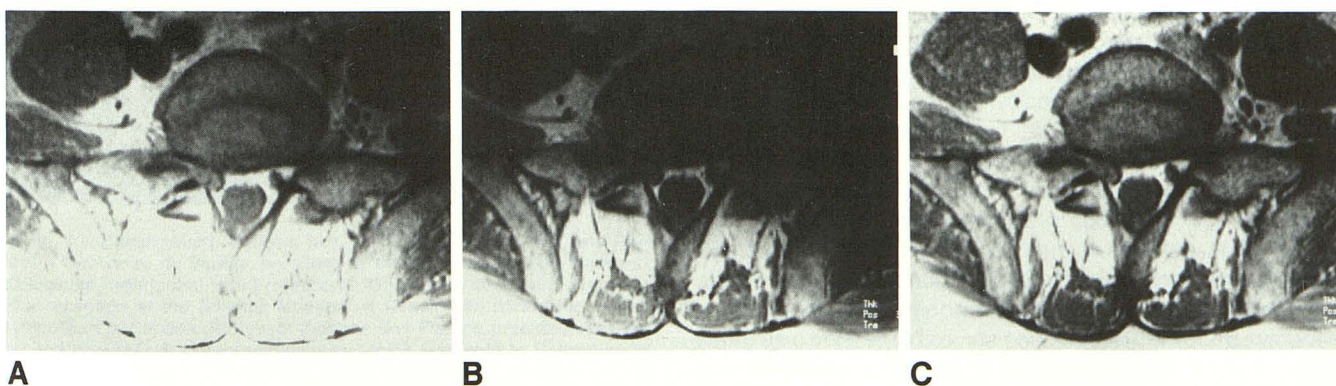


Fig. 1.—Proton-density-weighted axial MR images before and after normalization using a 12 × 24 cm diameter flat surface coil. **A**, This image is windowed for visualization of the disk and prevertebral space with high signal obscuring the posterior soft tissues. **B**, Posterior soft tissues are well delineated but there is marked signal loss in anterior region. **C**, Normalized image shows equal distribution of signal intensity and good contrast in all regions.

Received February 23, 1990; revision requested April 16, 1990; revision received June 1, 1990; accepted June 5, 1990.

<sup>1</sup> Department of Radiology, Beth Israel Hospital, 330 Brookline Ave., Boston, MA 02215. Address reprint requests to R. R. Edelman.

<sup>2</sup> Department of Radiology, University Hospital, D-7900 Ulm, Federal Republic of Germany.

<sup>3</sup> Siemens Medical Systems, Inc., Iselin, NJ 08830.

<sup>4</sup> Department of Radiology, New England Deaconess Hospital, Boston, MA 02215.

images for photography, so that all regions of the spine could be well assessed. In images without normalization, it was sometimes necessary to rephotograph the images with two or more window settings in order to allow all regions of the spine to be evaluated adequately. Normalization never caused a loss of diagnostic information. Within the prevertebral region, noise was more evident than in nonnormalized images; however, these regions were commonly uninterpretable in nonnormalized images because they appeared too dark.

### Discussion

The function of the B<sub>1</sub>-field distribution of a circular current-carrying loop with a radius *r* along the *y* axis perpendicular to the coil plane is given by the formula

$$B_1(y) = \mu_0 r^2 / [2(r^2 + y^2)^{3/2}]$$

The B<sub>1</sub>-field distribution in practice is of course much more complex, depending on the various surface-coil designs [3]. Intensity-correction of surface-coil images has already been suggested [1, 2]. The algorithm for surface-coil image inten-

sity correction we employed is simpler to implement than previously described approaches, but is not a perfect approximation to the true surface-coil sensitivity profile; nonetheless, it routinely improves image quality and allows better visualization of distant structures. Reconstruction time is only marginally increased. Signal-to-noise is unaffected by this method, although noise distant from the coil is more apparent owing to the boosted intensity of both noise and signal. We conclude that signal normalization helps in image interpretation and improves the quality and consistency of the photographed images. It can be routinely employed in surface-coil imaging of the spine and may be of value in other surface-coil applications, such as shoulder or orbit imaging.

### REFERENCES

1. Axel L, Costantini J, Listerud J. Intensity correction in surface coil imaging. *AJR* 1987;148:418-420
2. Lufkin RB, Sharpless T, Flannigan B, Hanafee W. Dynamic-range compression in surface-coil MRI. *AJR* 1986;147:379-382
3. Stoetter E. Instrumentation. In: Edelman RR, Hesselink J, eds. *Clinical magnetic resonance imaging*. Philadelphia: Saunders, 1990:355-376