

Safety of Magnetic Resonance Imaging After Implantation of Stainless Steel Embolization Coils

Timothy C. Slesnick¹ · Jenna Schreier² · Brian D. Soriano³ · Shelby Kutty⁴ · Arni C. Nutting⁵ · Dennis W. Kim¹ · Andrew J. Powell² · Anne Marie Valente²

Received: 2 April 2015 / Accepted: 3 August 2015 / Published online: 11 August 2015
© Springer Science+Business Media New York 2015

Abstract Stainless steel embolization coils (SSEC) have been used for over four decades for vascular occlusion. Recently, the safety of these coils in a magnetic resonance environment has been called into question, with important ramifications for thousands of patients with existing coils in place. We performed a retrospective chart review at five tertiary care pediatric centers evaluating all children and young adults with implanted SSEC who underwent magnetic resonance imaging (MRI). Data reviewed included demographics, coil implantation, MRI studies, and follow-up evaluations. Complications such as heating, discomfort, or device migration were specifically sought. Two hundred and ninety-seven patients with implanted SSEC underwent 539 MRI examinations. The median age at SSEC implantation was 2.3 years (1 week–23.2 years). The MRI studies were performed a median of 7.4 years (4 days–23.1 years) after implantation. No patients experienced any reported complications associated with their MRI examinations

during the study or at median follow-up post-MRI of 4.8 years (1 day–23 years). In this large, retrospective review of patients with implanted SSEC undergoing MRI, there were no reported adverse events. These findings support the recent change by Cook Medical Inc. of their standard embolization coils from a designation of magnetic resonance unsafe to conditional.

Keywords Stainless steel embolization coils · Magnetic resonance imaging · Safety · Pediatrics · Congenital heart disease

Abbreviations

ASTM American Society for Testing and Materials
MR Magnetic resonance
MRI Magnetic resonance imaging
SSEC Stainless steel embolization coils

✉ Timothy C. Slesnick
slesnickt@kidsheart.com

Jenna Schreier
jenna.schreier@cardio.chboston.org

Brian D. Soriano
brian.soriano@seattlechildrens.org

Shelby Kutty
skutty@unmc.edu

Arni C. Nutting
nutting@muscc.edu

Dennis W. Kim
kimd@kidsheart.com

Andrew J. Powell
andrew.powell@cardio.chboston.org

Anne Marie Valente
anne.valente@cardio.chboston.org

¹ Emory University School of Medicine, Children's Healthcare of Atlanta, 1405 Clifton Road, Atlanta, GA 30322, USA

² Boston Children's Hospital, Harvard Medical School, Boston, MA, USA

³ Seattle Children's Hospital, University of Washington School of Medicine, Seattle, WA, USA

⁴ Children's Hospital and Medical Center, University of Nebraska College of Medicine, Omaha, NE, USA

⁵ Medical University of South Carolina Children's Hospital, Charleston, SC, USA

Introduction

Stainless steel embolization coils (SSEC) were first introduced in the 1970s for embolization of arterial and venous vessels [10, 11, 24] and are commonly used in children and adults with congenital heart disease. They have become increasingly utilized for vascular occlusions in a wide variety of settings, ranging from native connections, such as aorto-pulmonary collateral arteries or a patent ductus arteriosus, to closure of surgically created structures, such as Blalock–Taussig shunts. Implanting SSEC has been successful at vascular occlusion; however, a secondary effect has been limitations on magnetic resonance imaging (MRI) for these patients. It is widely known that these embolization coils can create significant susceptibility image artifacts when patients undergo MRI [9]. Moreover, with MRI there are potential safety concerns including localized temperature elevation, induction of electrical currents, or movement and/or dislodgement of the device [22].

In 1997, the US Food and Drug Administration Center for Devices and Radiological Health, in recognition of the increasing use of MRI, began to publish standards for safety of implants and other medical devices in MRI [23]. Over the next several years, the American Society for Testing and Materials (ASTM) developed several standards for testing methods and guidance regarding these devices [1–4], and in August 2005, due to concerns over ambiguity in the terms being applied to these devices by manufacturers, ASTM F2503-05 was published [5]. This document revised the classification scheme for medical devices to include the designations of magnetic resonance (MR) safe, MR conditional, and MR unsafe.

Initially, SSEC did not carry a specific MR designation. Several years after the publication of ASTM F2503-05, the Standard Embolization Coil (Cook Medical Inc., Bloomington, IN), which is composed of stainless steel, was given a designation of MR unsafe [18] by the manufacturer based on internal benchtop testing by the company, though no clinical studies evaluating safety were performed. However, many centers continued to perform MRI scanning of patients with implanted SSEC because the perceived benefits were felt to outweigh the potential risks for a particular patient or the performing centers were unaware of the MR unsafe designation. To our knowledge, there are no studies evaluating the safety of SSEC in patients undergoing clinical MRI. We therefore undertook a multicenter review to assess the safety of performing MRI studies on pediatric and young adult patients with implanted SSEC.

Materials and Methods

The Cardiology and Radiology databases were retrospectively reviewed at five tertiary care pediatric hospitals (Boston Children's Hospital; Children's Healthcare of Atlanta; Children's Hospital and Medical Center, Omaha, Nebraska; Medical University of South Carolina; and Seattle Children's Hospital) with institutional board approval from all five sites. All patients who were aged <30 years, had undergone implantation of a SSEC, and subsequently underwent MRI were eligible for inclusion. Only those patients with complete demographic data, including date of birth, date of coil implant, date of MRI scan, and results of MRI were included. When possible, follow-up data were also recorded including safety information regarding the MRI examinations. For patients who underwent multiple MRI studies after coil implantation, all scan-related data were recorded and analyzed for safety. Chart review of both the MRI report and, when available, clinic notes was performed to assess for any MRI-related complications. The specific complications that were sought for included heating, discomfort, and device migration.

Ages at coil implantation, age at MRI, time from coil implantation to MRI, and time from MRI to most recent follow-up were recorded. For patients with multiple examinations, time from coil implantation to MRI and time from MRI to most recent follow-up were calculated only for their first MRI. Results are reported as median values and range. Literature and manufacturer database queries were conducted to search for prior reports on safety events with these coils. Both PubMed and Europe PubMed Central were searched using term combinations of “stainless steel embolization coil,” “safety,” and “magnetic resonance.” The Manufacturer and User Facility Device Experience (MAUDE) database [13] (<http://www.fda.gov/medicaldevices/deviceregulationandguidance/postmarketrequirements/reportingadverseevents/ucm127891.htm>) was queried for device reports on the Cook SSEC.

Results

A total of 297 patients with implanted SSEC underwent 539 MRI examinations at the five institutions. Median patient age at the time of coil implantation was 2.3 years (range 1 week–23.2 years) with the majority in children <5 years of age (Fig. 1a). Two hundred and eighteen patients (73 %) had SSEC placed in aorto-pulmonary or veno-venous collaterals. Additionally, 55 patients had coils placed in a patent ductus arteriosus, 18 had embolization of

a modified Blalock–Taussig shunt, four had occlusion of an intracardiac baffle leak, and two had occlusion of coronary fistulas or accessory vessels. The median number of coils placed was 3 (1–55 coils).

The median age at MRI was 11.6 (0.2–28.9) years (Fig. 1b). MRI was performed a median of 7.4 years (4 days–23.1 years) after coil implantation (Fig. 1c). Ten patients underwent MRI scanning within 6 weeks of the time of implantation, with a minimal interval of 4 days between SSEC implantation and MRI. Among the study group, 176 patients had one MRI examination, 65 patients had two examinations, and 56 patients had three or more

examinations, with a maximum of 12 examinations in one patient over an 11-year period.

The most common MRI examination types performed were cardiac (330 examinations, 61.2 %) and brain (141 examinations, 26.2 %) (Fig. 2a). Gadolinium-based contrast was utilized in 268 examinations (49.8 %), and 475 examinations (96.2 %) were performed on a 1.5-T scanner (Fig. 2b). Four hundred and six examinations (83 %) were performed without any sedation, 59 examinations (12.1 %) were done under general anesthesia, and 24 examinations (4.9 %) were performed with conscious sedation.

No patients experienced any complications during the MRI examinations at either 1.5- or 3-T field strengths. Specifically, there were no reports of heating, chest discomfort, or device mobilization documented in the technical notes or MRI reports. Of the 297 patients, 265 (89.2 %) had at least one follow-up visit with a cardiologist after their MRI examination available for review. The median length of time from MRI to most recent follow-up was 4.8 years (1 day–23 years). At these follow-up visits, there were no reported MRI-related complications in any of the patients.

The PubMed and Europe PubMed Central queries yielded neither relevant manuscripts nor case reports. The

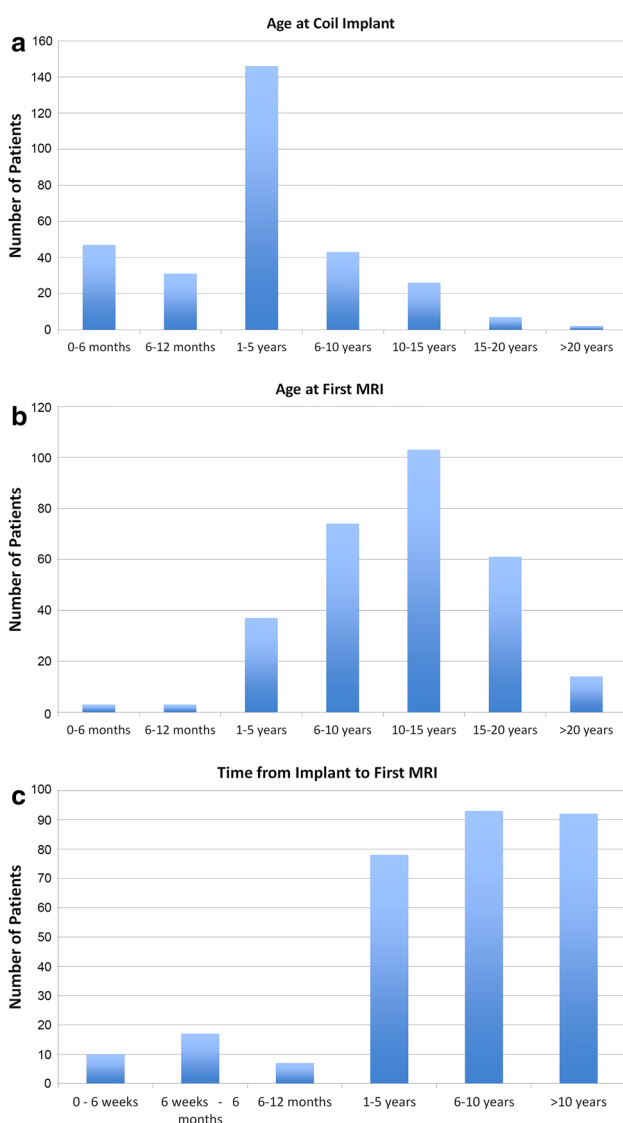


Fig. 1 a Age at SSEC implantation. b Age at first MRI. c Interval between coil implantation and first MRI scan

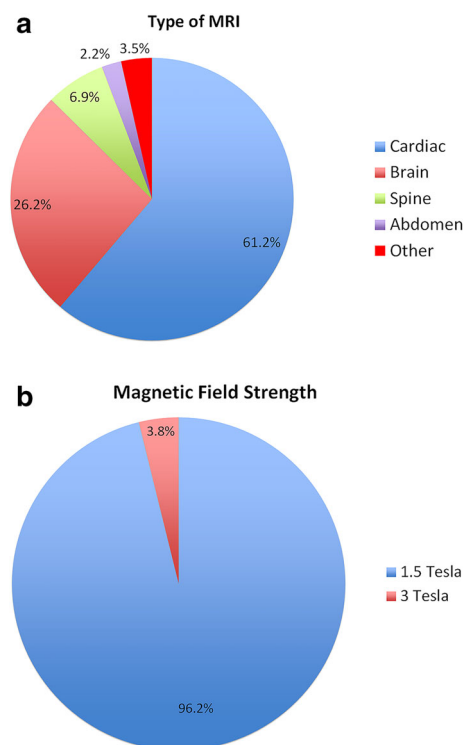


Fig. 2 a Type of MRI performed. b Field strength of the MRI magnet for MRI scans

query of the MAUDE database generated 10 medical device reports for the Cook SSEC. Five of these described a localized infection after implantation of SSEC that was subsequently treated. The other five reports documented concerns regarding the delivery of the devices, all of which were resolved by the clinical team and were not deemed to have resulted in harm to the patients. No reports of complications relating to MRI examinations in patients with SSEC were identified.

Discussion

This report is the first to examine the safety of MRI in patients with implanted SSEC. Our retrospective multicenter study did not identify any adverse safety events in 297 patients with implanted SSEC who underwent a total of 539 MRI examinations over a median follow-up of 4.8 years after the first MRI examination. Of note, nearly all of the examinations were with 1.5-T scanners and most were either cardiac or brain examinations. In addition, a query of the MAUDE database and PubMed databases did not identify any complications relating to MRI examinations in patients with implanted SSEC. Based on these data, it seems reasonable to conclude that MRI examinations with 1.5-T scanners in patients with implanted SSEC have a very low safety risk.

Metallic implants and devices with ferromagnetic properties may pose a number of risks to patients undergoing MRI. Localized temperature elevation, induction of electrical currents, or movement and/or dislodgement of the device itself may occur [8, 14, 15, 19–22]. In addition to these physical risks, susceptibility image artifacts caused by ferromagnetic devices can lead to difficulty in interpretation.

SSEC have been utilized since the mid-1970s for occlusion of arterial and venous vessels [10, 11, 24]. Initially, there was little consideration given toward the implications of coil implantation regarding future MRI examinations. Many were implanted in children within a patent ductus arteriosus, a procedure that is typically curative from a cardiovascular standpoint so that subsequent cardiac MRIs are not routinely anticipated. Even for these children, however, the possibility remains that they may require MRI examinations for non-cardiac indications (e.g., neurologic, oncologic, and orthopedic) later in life.

For the first several decades, there was no specific manufacturer labeling for SSEC from a safety standpoint. As the SSEC do exhibit ferromagnetic properties, it was recognized that the strong magnetic field of the MRI scanner could cause torque and deflection. Since it was thought that coils become firmly incorporated into their

implanted vessel after approximately 6 weeks, the long-standing recommendation was that it was safe to image patients thereafter since sufficient time had elapsed to ensure the coils were in stable position [22].

Subsequent to the ASTM establishment of MR safe, MR conditional, and MR unsafe designations for metallic implanted devices, Cook Medical Inc. undertook further benchtop testing of their SSEC conforming to the techniques described in ASTM F2052 [1]. These unpublished internal results led the manufacturer to label the SSEC as MR unsafe [18]. As a result, many patients were restricted from undergoing any kind of MRI. Within the pediatric cardiology and radiology communities, however, there was concern that this benchtop testing did not accurately represent the *in vivo* condition of these implanted coils as it was based on a simple deflection model with the coil suspended in air on a filament. Whether implanted in venous or arterial structures, the coils are known to induce fibrosis. Thus, suspension in air with measurement of deflection may not provide an accurate assessment of the coils' behavior *in vivo*. Similar logic has been applied to other medical devices, particularly those fixated in rigid structures such as bone [16].

In 2006, Cook Medical Inc. introduced their MReye Embolization Coils as an alternative to SSEC [7]. Composed of a nickel-based superalloy, Inconel, these coils have a designation of MR conditional and create substantially less imaging artifact than stainless steel coils (Figs. 3, 4). These MReye coils joined the existing range of platinum coils as commercially available alternatives to SSEC [12]. Cook Medical Inc. subsequently discontinued the sale of their stainless steel coils on April 30, 2012 [6], but thousands of patients have existing coils already implanted, so the issue of safety of the SSEC in the MRI environment remains relevant. At the time of initiation of this project, several authors and other members of the scientific community expressed their concerns regarding the SSEC MR unsafe designation to Cook Medical Inc. Further non-clinical benchtop testing was pursued by the manufacturer, and on March 14, 2012, the designation on the Standard Embolization Coil was changed to MR conditional [17].

Limitations

The current study is a retrospective review and as such is subject to several inherent limitations. For many patients, the specific MRI pulse sequences performed and specific absorption rates were not available in retrospective review of the examinations, and thus, these factors could not be comprehensively evaluated in this study. All but 19 examinations were performed at 1.5-T field strength, so the

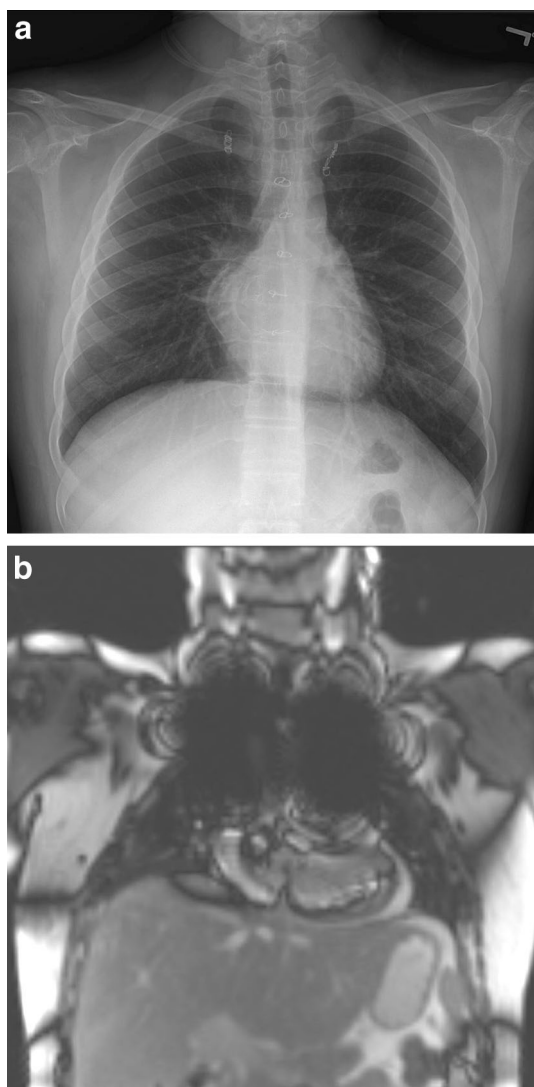


Fig. 3 Examples of SSEC coils by chest radiograph and MR image. Typical imaging artifact from stainless steel embolization coils in a patient with single-ventricle heart disease who had coils placed within the left and right internal mammary arteries. Coil position is shown on a posterior–anterior chest radiograph (**a**) and on a scout coronal localizer MR image. Note the large artifact occupying the majority of the right and left upper chest (**b**)

evaluation at 3-T was very limited. No prospective safety analyses were performed either at the time of MRI examinations or follow-up visits, and thus, the complication rates represent only what was reported by the patient and clinicians within the medical record. It is possible that some patients experienced mild heating of their coils of which they were unaware, though no adverse symptoms of chest pain or discomfort were reported. Additionally, since pre- and post-procedure chest radiographs were not performed, the possibility of minor movement of the SSEC within the embolized vessels cannot be excluded.

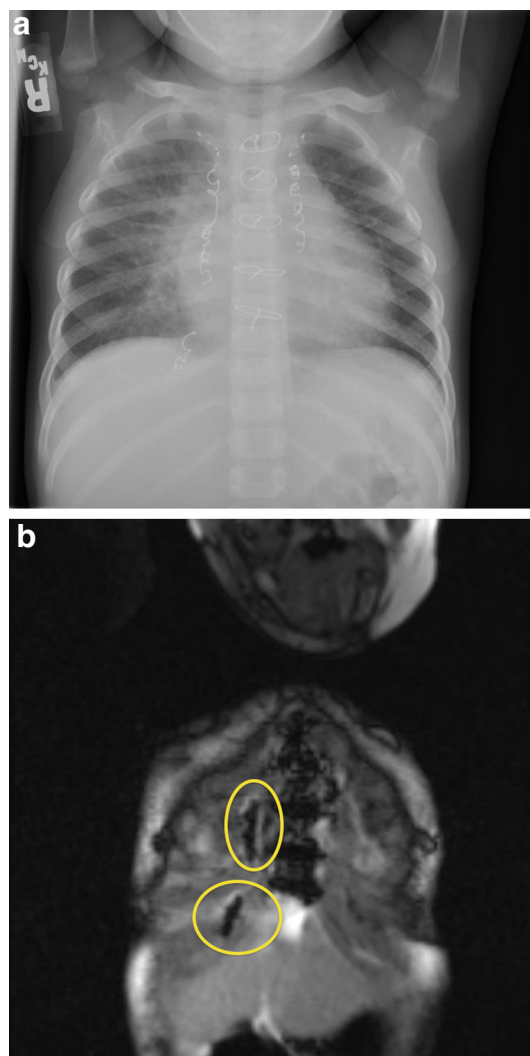


Fig. 4 Examples of Inconel coils by chest radiograph and MR image. Typical imaging artifact from Inconel-based embolization coils in a patient with single-ventricle heart disease with coils in both the left and right internal mammary arteries as well as veno-venous collateral vessels. Coil position is shown on a posterior–anterior projection plain film radiograph (**a**) and on a scout coronal localizer image through the anterior chest wall. The relatively small artifacts are seen immediately to the patient's right of the sternum (*yellow circles*) (**b**)

Conclusions

In this large, retrospective study assessing the safety of MRI in patients who have undergone previous endovascular implantation of SSEC, there were no reported adverse events related to SSEC. These findings support the recent change by Cook Medical Inc. of their standard embolization coils from a designation of MR unsafe to MR conditional. Patients with previously implanted SSEC should be considered to have a very low safety risk of MRI examinations on 1.5-T scanners.

Acknowledgments There are no specific acknowledgements. None of the authors received any funding for this project or manuscript.

Compliance with Ethical Standards

Conflict of interest The authors have no relevant financial or non-financial interests to disclose.

References

1. ASTM F2052–06e1 (2006) Standard test method for measurement of magnetically induced displacement force on medical devices in the magnetic resonance environment. ASTM International, West Conshohocken
2. ASTM F2119–01 (2001) Standard test method for evaluation of MR image artifacts from passive implants. ASTM International, West Conshohocken
3. ASTM F2182–02a (2002) Standard test method for measurement of radio frequency induced heating near passive implants during magnetic resonance imaging. ASTM International, West Conshohocken
4. ASTM F2213–06 (2006) Standard test method for measurement of magnetically induced torque on medical devices in the magnetic resonance environment. ASTM International, West Conshohocken
5. ASTM F2503–05 (2005) Standard practice for marking medical devices and other items for safety in the magnetic resonance environment. ASTM International, West Conshohocken
6. Cook Medical memo for discontinuation of stainless steel embolization coils (2012). http://www.cookmedical.com/di/content/mmedia/PI_SS_Coil_Discontinuation.pdf. Accessed 1 Aug 2013
7. Cook Medical MR eye embolization coil brochure (2006). <http://www.cookmedical.com/di/content/mmedia/MREYE306.pdf>. Accessed Jan 8 2013
8. Dedini RD, Karacozoff AM, Shellock FG, Xu D, McClellan RT, Pekmezci M (2013) MRI issues for ballistic objects: information obtained at 1.5-, 3- and 7-Tesla. *Spine J* 13:815–822
9. Garg R, Powell AJ, Sena L, Marshall AC, Geva T (2005) Effects of metallic implants on magnetic resonance imaging evaluation of Fontan palliation. *Am J Cardiol* 95:688–691
10. Gianturco C, Anderson JH, Wallace S (1975) Mechanical devices for arterial occlusion. *Am J Roentgenol Radium Ther Nucl Med* 124:428–435
11. Goldstein HM, Wallace S, Anderson JH, Bree RL, Gianturco C (1976) Transcatheter occlusion of abdominal tumors. *Radiology* 120:539–545
12. Grifka RG, Fenrich AL, Tapio JB (2008) Transcatheter closure of patent ductus arteriosus and aorto-pulmonary vessels using non-ferromagnetic Inconel MREye embolization coils. *Catheter Cardiovasc Interv* 72:691–695
13. Gurtcheff SE (2008) Introduction to the MAUDE database. *Clin Obstet Gynecol* 51:120–123
14. Kainz W (2007) MR heating tests of MR critical implants. *J Magn Reson Imaging* 26:450–451
15. Liu Y, Chen J, Shellock FG, Kainz W (2013) Computational and experimental studies of an orthopedic implant: MRI-related heating at 1.5-T/64-MHz and 3-T/128-MHz. *J Magn Reson Imaging* 37:491–497
16. McComb C, Allan D, Condon B (2009) Evaluation of the translational and rotational forces acting on a highly ferromagnetic orthopedic spinal implant in magnetic resonance imaging. *J Magn Reson Imaging* 29:449–453
17. Published memo from cook medical on designation change for stainless steel embolization coils to MR conditional. Dated March 14 2012
18. Published memo from cook medical on designation of stainless steel embolization coils changing to MR unsafe. Dated Feb 25 2011
19. Shellock FG (2007) Comments on MR heating tests of critical implants. *J Magn Reson Imaging* 26:1182–1185
20. Shellock FG, Slimp G (1990) Eddy-current-induced artifacts caused by an “MR-compatible” halo device. *Radiology* 175:586
21. Shellock FG, Slimp G (1990) Halo vest for cervical spine fixation during MR imaging. *AJR Am J Roentgenol* 154:631–632
22. Shellock FG, Morisoli S, Kanal E (1993) MR procedures and biomedical implants, materials, and devices: 1993 update. *Radiology* 189:587–599
23. U.S. FDA, CDRH (1997) A primer on medical device interactions with magnetic resonance imaging systems. <http://www.fda.gov/MedicalDevices/DeviceRegulationandGuidance/GuidanceDocuments/ucm107721.htm>. Accessed 16 Dec 2012
24. Wallace S, Gianturco C, Anderson JH, Goldstein NH, Davis LJ, Bree RL (1976) Therapeutic vascular occlusion utilizing steel coil technique: clinical applications. *AJR Am J Roentgenol* 127:381–387