



PHILIPS

O-MAR

MR software

Orthopedic Metal Artifact Reduction

Distortion correction in the presence of a orthopedic implant

By S. Hey, D. Hoogenraad, V. Elanchezhian, M. van Meel and F. Admiraal-Behloul

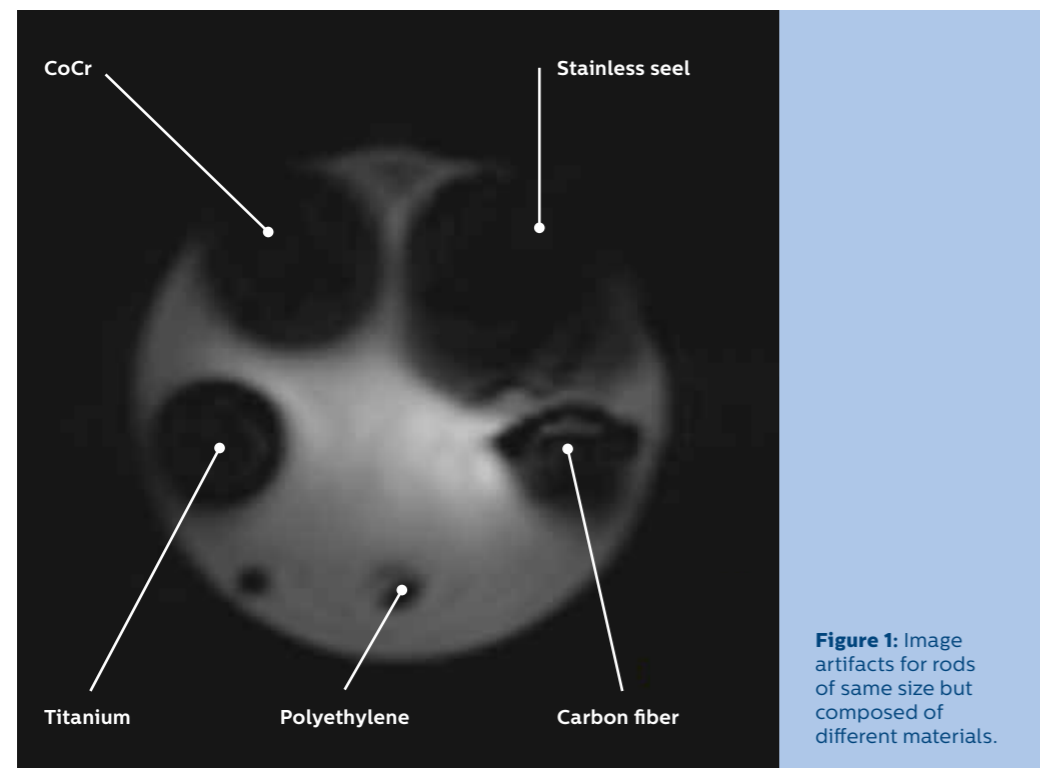
In recent years the number of patients with orthopedic implants has increased significantly.¹ The increased life expectancy in many developed and developing countries is certainly the largest contributing factor to this growth. As life expectancy increases, conditions such as osteoarthritis and osteoporosis become increasingly common, and those conditions can be alleviated with implants. In addition, the growing popularity of high risk, high-impact sports has also contributed to the rise in implants, because these sports can result in injuries that require implants. Furthermore, advances in implant technology, as well as in minimally invasive joint reconstruction surgery, have led surgeons to become more willing to undertake surgery. Joint reconstruction procedures are becoming minimally invasive, and more reliable treatments are becoming available. There are several conditions that a patient can develop after receiving an implant²: osteolysis (loss of bone around the implant), metallosis (metal poisoning), heterotopic ossification (bone forming outside the skeleton), osteonecrosis (bone death due to lack of blood; it can also lead to implant failure), component loosening (considered one of the most serious long term indications that might require a revision surgery). Magnetic Resonance Imaging (MRI) is a modality of choice for the non-invasive visualization of both bone and surrounding soft tissues. However, in the presence of orthopedic implants, conventional MSK MR imaging sequences show severe image artifacts^{3,4}, which limit the adoption of MR in the follow-up of patient with orthopedic implants.

Why do artifacts occur around metal implants?

Magnetic susceptibility indicates the degree of magnetization of a material in response to an applied magnetic field. Tissues with differing magnetic susceptibility will have different static magnetic field (B_0) strength within them; adjacent tissues of differing magnetic susceptibility have microscopic magnetic field gradients between them. The Larmor precession frequency in those tissues will therefore be different. These tiny gradients cause dephasing within a voxel, which leads to reduced signal. The magnetic susceptibility of metal is much higher than that of tissue, such that around metal, very large variations in Larmor frequency occur. This not only causes signal reduction, but also signal loss. So called signal pile-ups can also occur due to non-linear frequency-position mapping. Slice profile selection also relies on local precession frequency variations and is equally affected by susceptibility variations, resulting in distorted slice profiles and consequently signal misregistration in the slice direction. Consequently, around metal implants, anatomy can be severely obscured.

The severity of the MRI artifact induced by an orthopedic implant depends on various factors including the implant material, size, shape and orientation of the implant, as well as the chosen imaging sequence. Orthopedic implants are made from a range of materials which can be categorized as ferromagnetic (stainless steel, Cobalt Chromium (CoCr) alloys), non-ferromagnetic (titanium alloys) or non-metallic (ceramics, polyethylene). Figure 1 shows the MR image artifacts in a gradient echo acquisition for rods with equal size but composed of different materials.

The size, shape and orientation of an implant also affect the severity of the observed artifact. Orthopedic implants may contain a stem or rod (e.g. total hip replacements). If this geometry is aligned with the direction of the main MRI magnetic field, images will show fewer artifacts than those where the stem is perpendicular to the main field.



How can metal artifacts be reduced?

Before scanning a patient with an orthopedic implant, the safety label of the implant must be checked. Only patients with MR safe or MR conditional implants can be accepted for an MR examination. In case of MR conditional implants the MR conditional values given by the implant manufacturer must be applied throughout the whole MR examination. In this paper, all described techniques are applicable only for MR Safe or MR conditional implants when strictly adhering to the MR Conditional values.

There are many ways to reduce metal artifacts in MRI. Do not use gradient echo based sequences because they are more prone to metal artifacts (especially EPI) causing the size of the artifact in this type of sequence to be more pronounced. Use spin echo based sequences because they are less affected by signal loss since they use RF refocusing pulses to return the T_2^* decay of transverse magnetization to T_2 decay. When using turbo spin echo (TSE), reduce the echo spacing to collect more echoes in an echo train prior to total signal decay.

Since geometric distortions are caused by altered Larmor frequencies around metal implants, another technique to reduce the size of the artifacts is to increase the receiver bandwidth (rBW). This helps reduce the range of resonant frequencies over which

the distortion is spread to cover a smaller pixel range, containing the in-plane geometric distortion in a smaller area. An increased rBW will also allow a shorter echo-spacing in the TSE echo train, and a shorter minimum TE, which are required for T1W and PDW images. However, because higher rBW reduces SNR, a compromise has to be found between required SNR and acceptable geometric distortion. On every Philips system such optimizations are chosen when selecting the Metal Artifact Reduction Sequence (MARS).

In general, choosing a higher in-plane and through-plane resolution also reduces geometric distortions in similar ways as the increased receiver bandwidth. The above described techniques deliver artifact reduction but only to a certain extent. To further reduce the artifacts more advanced techniques must be applied.

O-MAR* for in-plane artifact reduction

Orthopedic Metal Artifact Reduction (O-MAR) is a combination of the MARS and View Angle Tilting (VAT) technique. VAT is an efficient technique for in-plane artifact correction.⁵ It uses an extra gradient in the slice select direction during the signal read-out, and the slice is effectively viewed from an angle (see Figure 2).

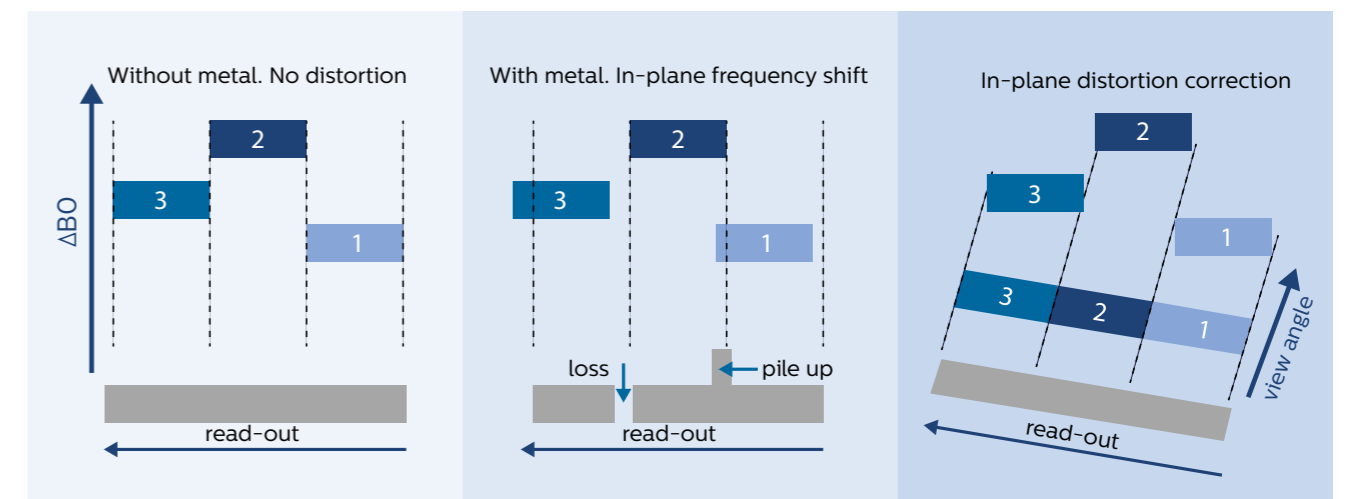


Figure 2: View Angle Tilting principle. In the presence of metal implants frequency shifts occur, resulting in in-plane signal loss or pile up. By tilting the readout direction using a gradient on the slice select axis during readout that is of the same amplitude as the slice select gradient, the received signals can be projected into the correct pixel of the image matrix. Although in-plane spatial distortion is considerably reduced, blurring can be introduced into the MR image.

The sum of artifactual frequency shifts in the slice select and the read-out (frequency encoding) direction results in a frequency shift with oblique direction. By viewing from this oblique angle during read-out, the received signals can be projected into the correct pixel of the image matrix. Although in-plane spatial distortion is considerably reduced, blurring can be introduced into the MR image.⁷ Blurring is minimized with increased rBW which is inherently the case with MARS. Furthermore, a SENSE reference scan is used which enables the use of both SENSE scan time reduction as well as CLEAR image reconstruction.

O-MAR XD* for in-plane and through-plane artifact reduction

O-MAR XD* combines the VAT method with the Slice Encoding for Metal Artifact Correction (SEMAC) technique to allow for susceptibility artifact reduction both in-plane and through-plane.⁸ SEMAC augments

the VAT method with phase encoding in the slice direction. 2D slices are excited just as in a standard multi-slice sequence, resulting in distorted profiles. In SEMAC, for each slice, a 3D image is formed to capture the through-plane distorted signal and map it back to its original slice location (see figure 3). Each slice can be regarded as a mini-volume applied multiple times according to the number of z-phase encoding steps, the SEMAC factor. Prior to the image reconstruction, data of the phase encoding steps of the different slices are processed and combined, resulting in an image corrected for through-plane distortion.

In order to achieve maximum through-plane correction, the SEMAC factor should be, equal or larger than the number of scanned slices, this requires longer acquisition time but similar to 3D vs 2D sequences increases SNR proportionally to the chosen SEMAC factor.

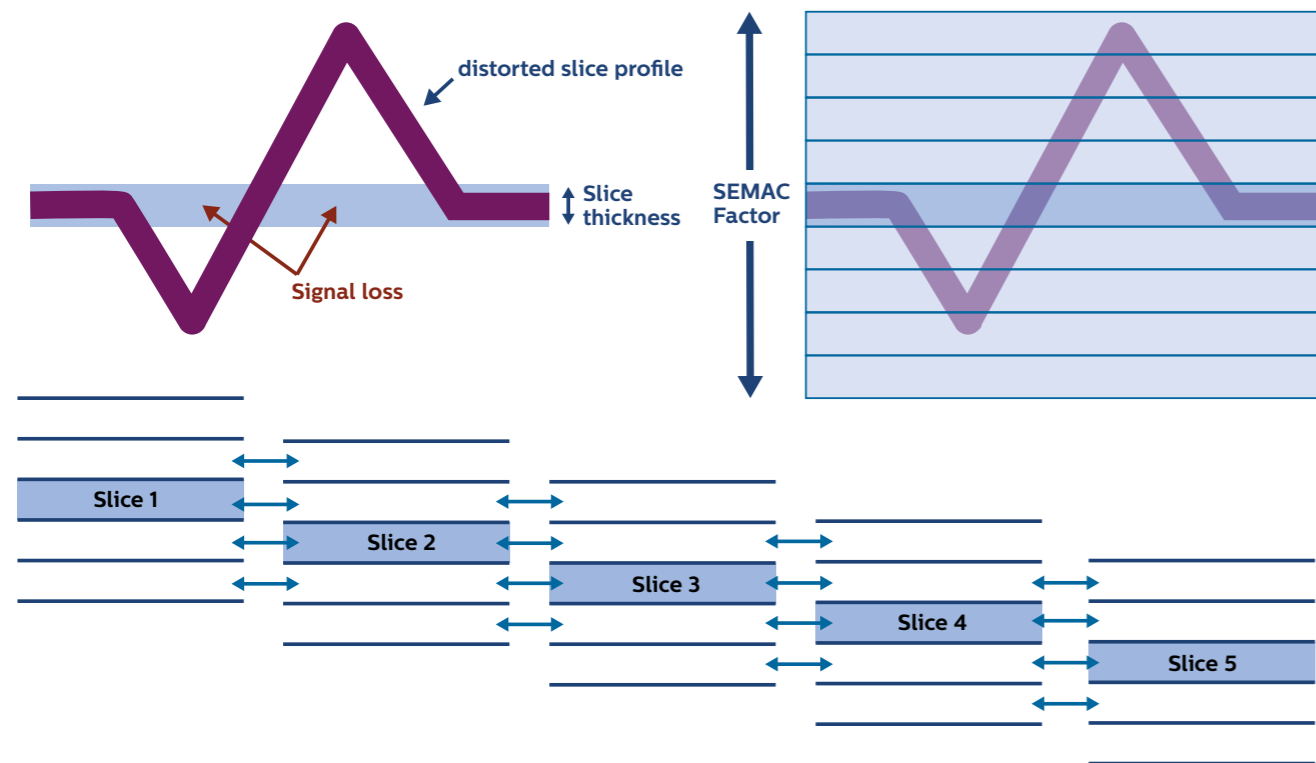


Figure 3: SEMAC principle: For each slice, a 3D image is formed to capture the through-plane distorted signal and map it back to its original slice location. The SEMAC factor is the number of z-phase encoding steps. Prior to the image reconstruction, data of the phase encoding steps of the different slices are processed and combined, resulting in an image corrected for through-plane distortion. Maximum through-plane correction can be obtained if the SEMAC factor is equal or larger than the number of scanned slices.

How well do O-MAR* and O-MAR XD* reduce metal artifacts?

For the evaluation of O-MAR* and O-MAR XD* we have run several tests on six selected MR Conditional Implant phantoms:

Hip-TC: Total hip implant with titanium stem and cup, and a ceramic head. This implant represents the most common modern hip implant and minimal artifact for an implant of this size⁹.

Hip_MM: Total hip implant with titanium stem and CoCr head and CoCr cup. This implant represents a commonly used metal-on-metal implant that produces a large artifact around the femoral head.

Hip_SOPC: Total hip implant with stainless steel stem and Oxinium head and polyethylene and CoCr cup. A common implant producing a large artifact for stem, head and cup. This is also an older type of implant, so it is representative of the patients who need reassessment 10, 15, or 20 years after implementation.

Knee_TPC: Total knee implant with titanium stem, polyethylene plate and CoCr femoral component. This composite implant is most commonly used although the specific materials may vary. The large CoCr femoral component represents the worst case for artifacts for such composite implants.

Spine_T: Spine titanium screws and fixation rod.

Spine_S: Spine stainless steel screws and fixation plate. For spine implants, the screws (not the fixation plate or rod) are most important for the orientation of the implant with respect to the field, since they are embedded in the anatomy where the size of the artifact is of most concern. The resulting parallel and perpendicular axes are indicated in Figure 4(c).

This set of selected phantoms mimics most implants. Shoulder implants (humeral head replacements) are of similar material and geometry as hip implants that replace the femoral head. Bone pins used for fracture fixation are customized to the individual fracture and stability needs and are expected to create comparable artifacts as knee or spine screws. Ankle implants represent a similar size and metal composition to hip or knee implants.

The selection was aiming at covering the extreme cases, i.e. ranging from very small artifacts induced by small non-ferromagnetic implants to big artifacts induced by big ferromagnetic implants. The expected results for medium relative artifact severity (medium sized ferromagnetic materials) can be interpolated from the results obtained for the extreme cases. In addition, most commonly used MR Conditional implants were selected.

All tests were performed on 1.5T Ingenua and 3.0T Achieva MR systems using the following dedicated receive coils: The hip implants were scanned using the posterior and anterior coil (Ingenua) and XL Torso coil (Achieva). The knee implant was scanned using the 8-channel knee coil on both Ingenua 1.5T and Achieva 3T. The spine implants were scanned using the posterior coil on Ingenua 1.5T and the spine coil on Achieva 3T. These coil choices match those that would be used for scanning the corresponding anatomy in vivo for hip, knee, and spine, respectively. The phantoms were oriented so that the implants were aligned with the main magnetic field in the same way as they would be in the case of in vivo scanning. For each test case, standard high bandwidth TSE (HBW-TSE), O-MAR* and O-MAR XD* scans were performed.

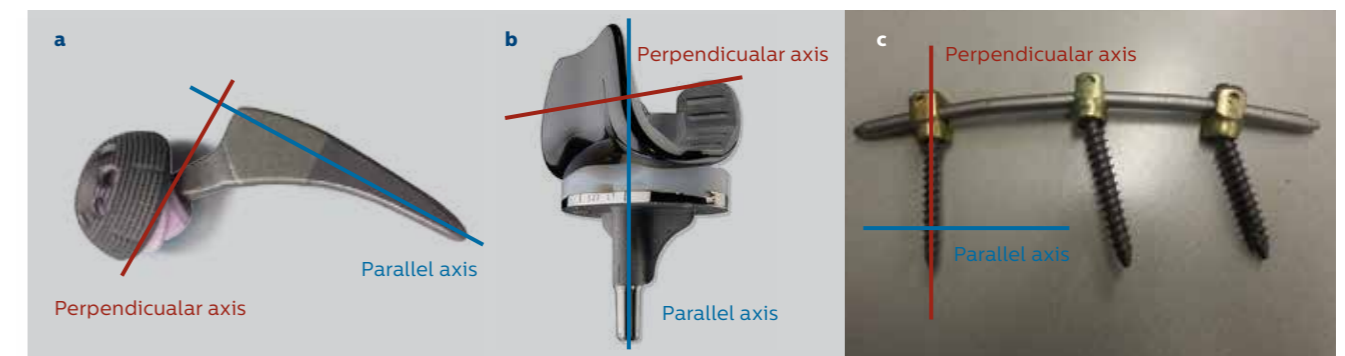


Figure 4: Parallel and perpendicular axis with respect to the main magnetic field for a total hip implant (a), a total knee implant (b) and spine screws (c) when scanned in vivo.

For each scan in each test case, the artifact size was assessed both in-plane and through-plane. For through-plane artifact, Multi-Planar Reformats (MPRs) along the readout direction were generated. A representative slice showing the full implant was selected on the high bandwidth TSE scan, and the corresponding slice from the O-MAR* and O-MAR XD* scans were selected. The size of the artifact was assessed using the same method, described hereafter, on each of the 3 images (see Figure 5).

The phantom area was masked in order to remove the influence of the background (these voxels are low intensity but should not be included in the voxel count for artifact size). A cumulative histogram of the voxel signal values within the mask was calculated from the corresponding histogram. The 80th percentile of the cumulative histogram was determined as a cutoff point in order to exclude high intensity artifacts. The 40th percentile was used for windowing. Binary windowing was applied by setting all voxel values below the 40th percentile to 0 and all voxel values above to 1. The total artifact size per implant was determined by counting the number of voxels with 0 signal intensity within the mask multiplied by the reconstructed voxel size in cm².




Figure 5: In-plane and through-plane artifact size assessment in a total knee implant phantom. For through-plane artifact, Multi-Planar Reformats (MPRs) along the readout direction were generated. Binary windowing was applied by setting all voxel values below the 40th percentile of a cumulative histogram to 0 and all voxel values above to 1. The artifact size was estimated by the number of 0 intensity voxels (within a mask excluding hypo-intense background voxels) multiplied by the reconstructed voxel size in cm².

Effect of implant size/geometry

In order to evaluate the effect of implant size and geometry, all six phantoms were scanned on 1.5T Ingenia and 3.0T Achieva using PDW image contrast and a parallel image orientation with respect to the implant geometry.

The results of our test are shown in Figure 6. O-MAR* and O-MAR XD* show smaller artifact size, with O-MAR XD* showing the smallest, for all implants on both 1.5T and 3.0T with an exception for the Spine_TC implant when looking at in-plane correction at 1.5T where O-MAR* and O-MAR XD* showed comparable smaller artifact sizes.

Effect of implant material

In order to evaluate the effect of the implant material, Hip_TC, Hip_MM and Hip_SOPC were scanned on 1.5T Ingenia and 3.0T Achieva using PDW image contrast and a parallel image orientation with respect to the implant geometry.

The results of our tests are showed in Figure 7. For all three types of implants, O-MAR* and O-MAR XD* showed lower artifact size than HBW_TSE for both in-plane and through-plane at 1.5T and 3.0T. Here again, O-MAR XD* showed the lowest artefact size in all tests.

Effect of image contrast choice

In order to evaluate the effect of the image contrast choice, Hip_TC was scanned on 1.5T Ingenia and 3.0T Achieva using PDW, T1W and T2W image contrast and a parallel image orientation with respect to the implant geometry.

The results of our tests are showed in Figure 8. Again, O-MAR* and O-MAR XD* showed lower artifact size in all image weightings with O-MAR XD* showing consistently the lowest artifact size compared to O-MAR* and HBW_TSE.

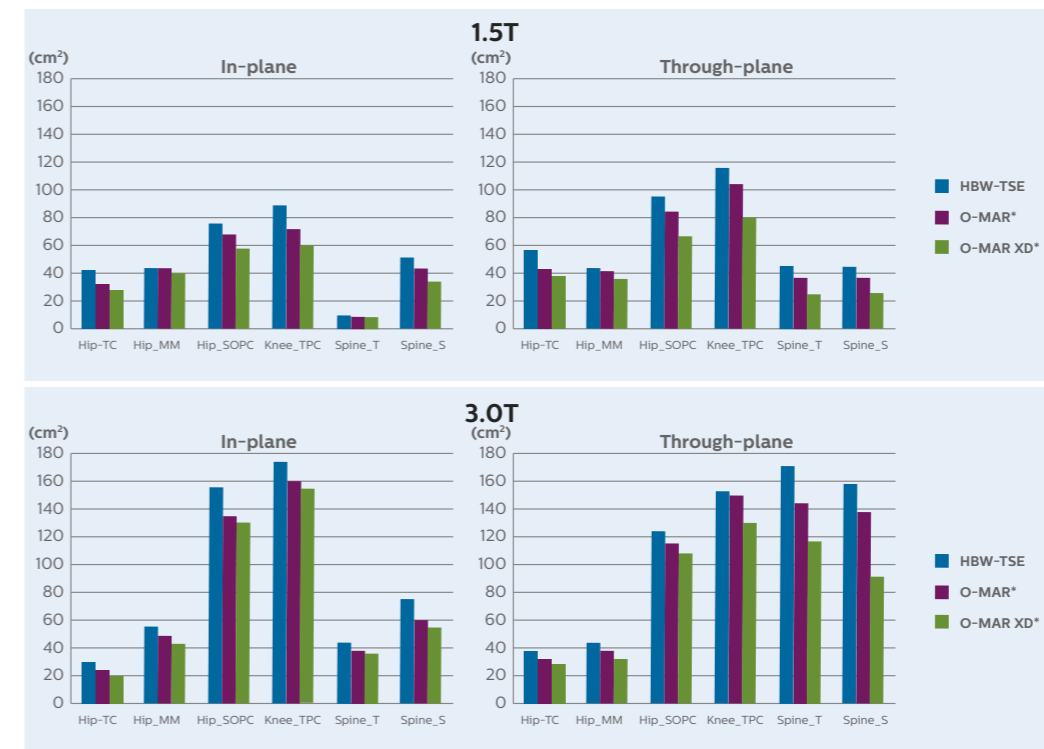


Figure 6: Effect of implant size and geometry. O-MAR* and O-MAR XD* show smaller artifact size, with O-MAR XD* showing the smallest, for all implants on both 1.5T and 3.0T with an exception for the Spine_TC implant when looking at in-plane correction at 1.5T where O-MAR* and O-MAR XD* showed comparable smaller artifact sizes.

Clinical examples

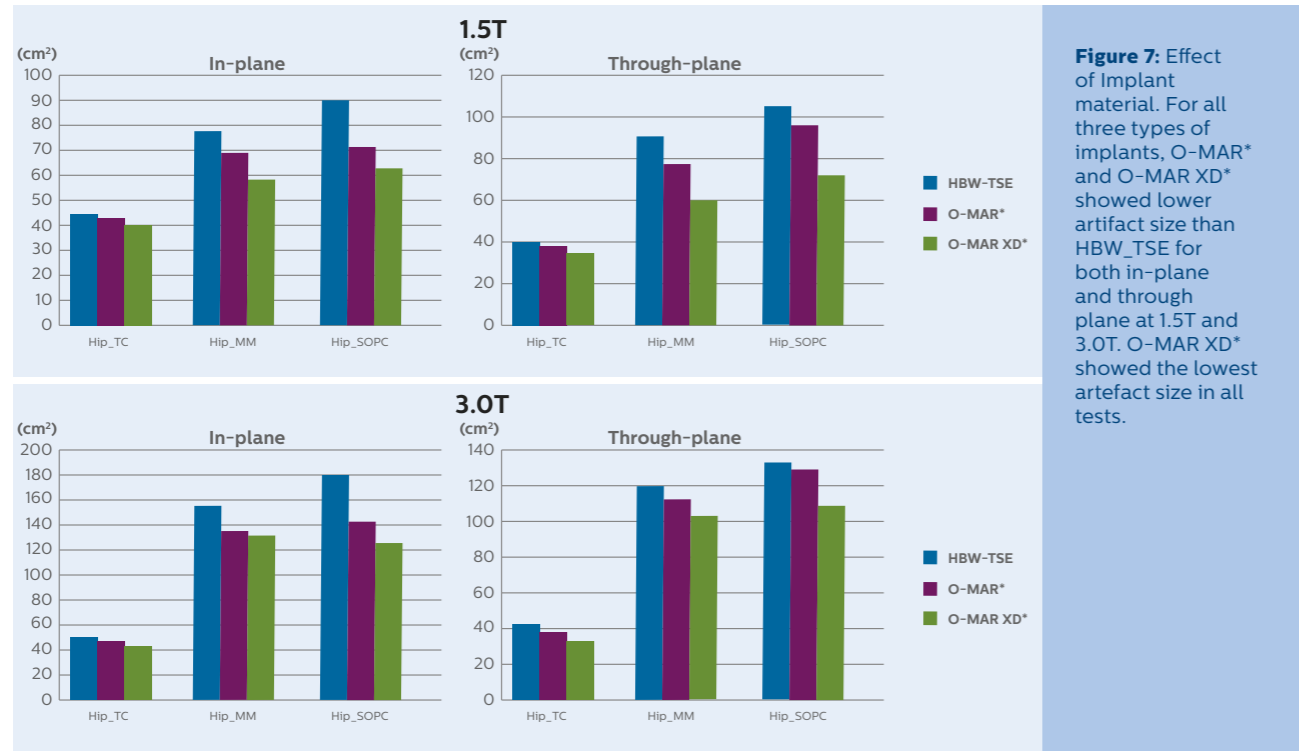
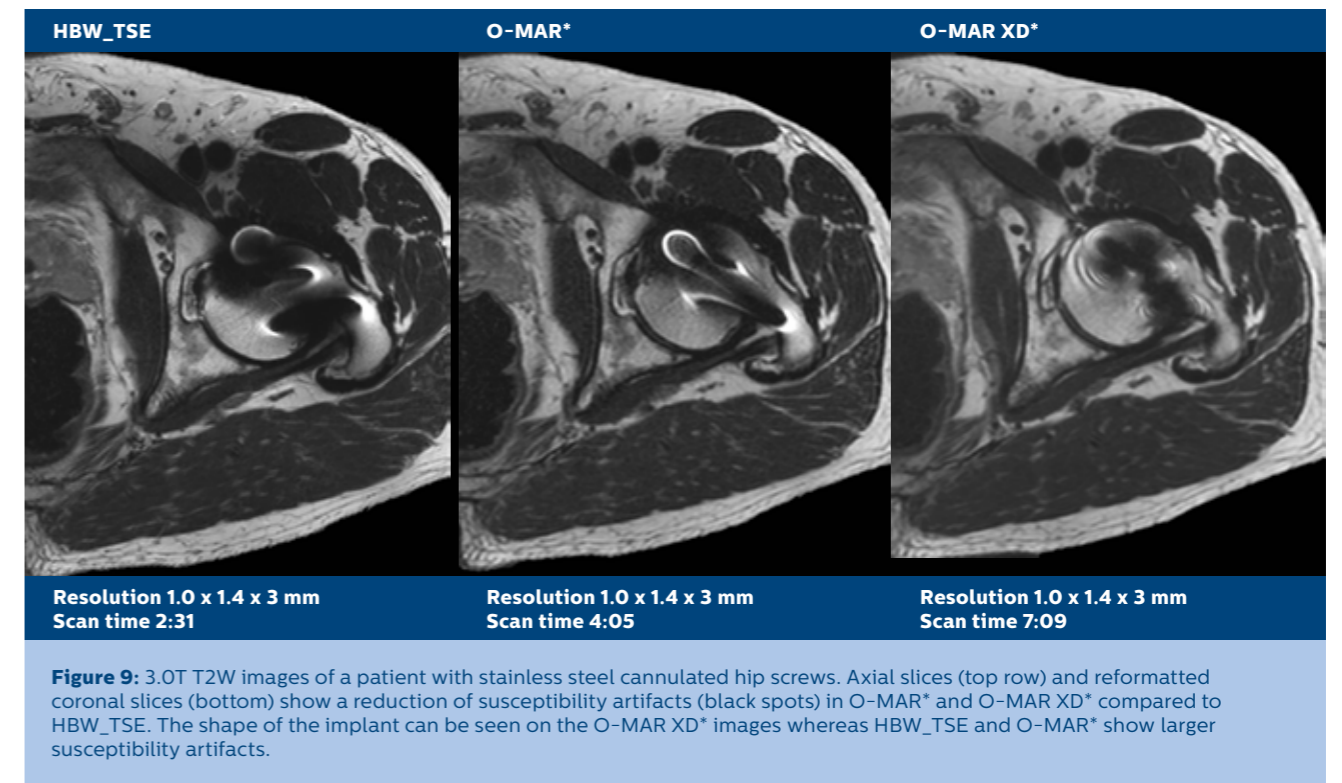
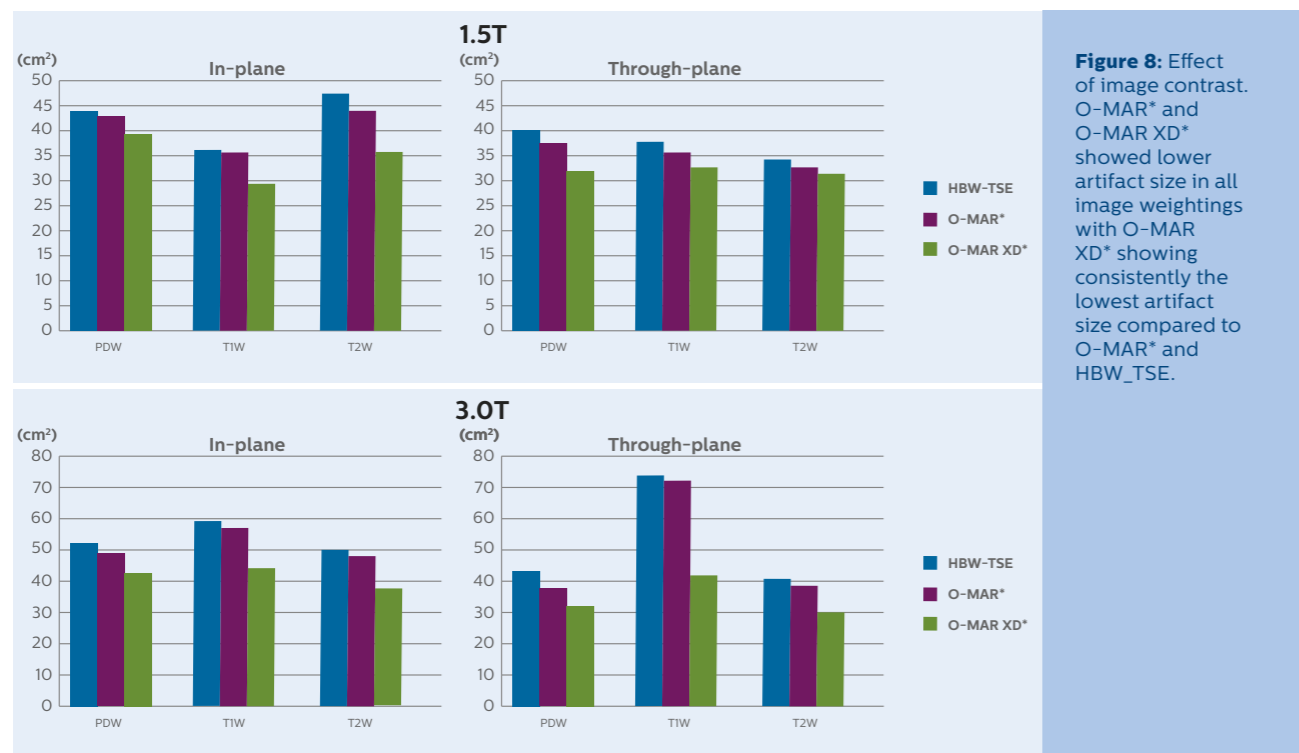
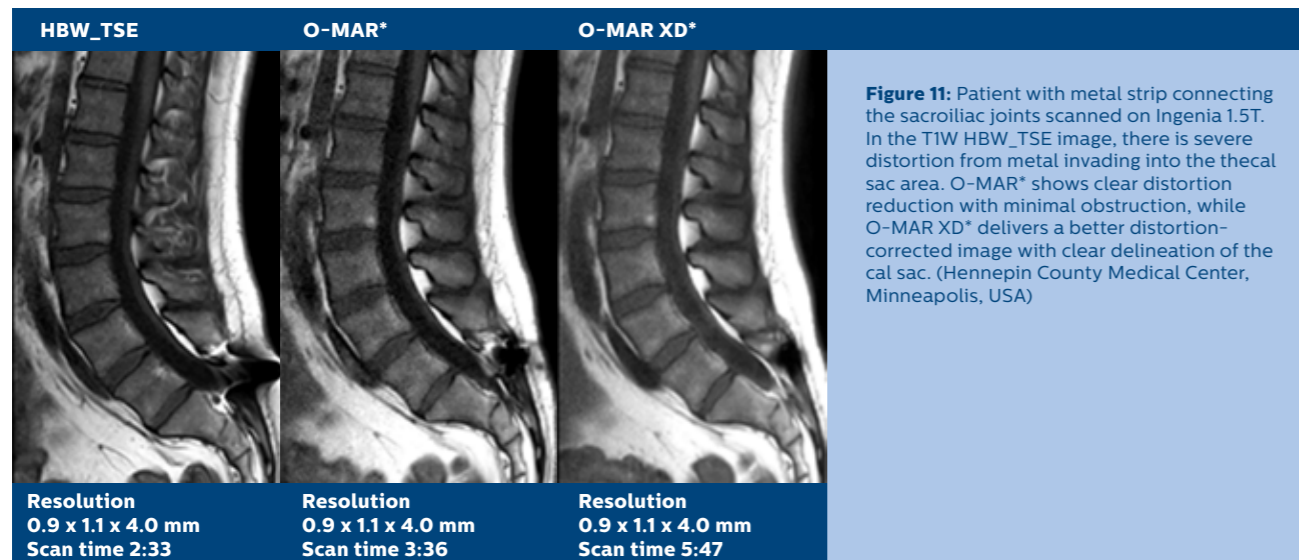
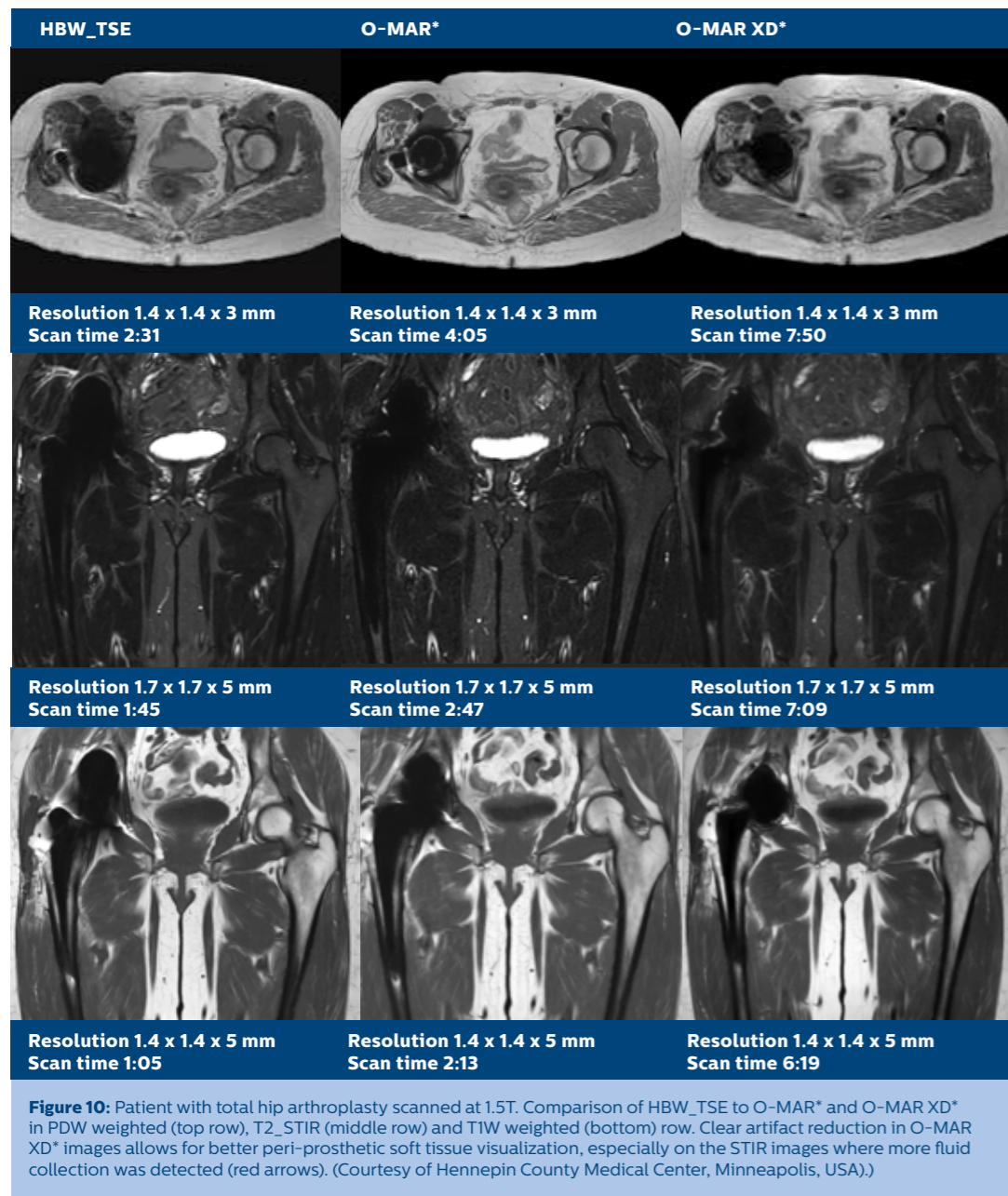


Figure 9 shows a T2W images of a patient with stainless steel cannulated hip screws. Because of the material composition and the perpendicular orientation of the screws compared to the main magnetic field, severe artifacts were observed on the HBW_TSE image, with some improvement on the O-MAR* image. Compared to HBW_TSE, O-MAR XD* successfully reduced the distortion artefacts and enabled the visualization of more soft tissue and bone.

Figure 10 shows the comparison of HBW_TSE , O-MAR* and O-MAR XD* in PDW, STIR, and T1W images of a patient with total hip arthroplasty. Compared to HBW_TSE, O-MAR* showed a clear artifact reduction especially in the axial PDW image, allowing a better periprosthetic soft tissue visualization. However, here again, O-MAR XD* showed the smallest artifact with minimal to no obstruction to periprosthetic soft tissue visualization, especially in the STIR image where small fluid collections could be detected only on the O-MAR XD* and not on O-MAR* nor HBW_TSE.

Figure 11 shows a patient with a metal strip connecting the sacroiliac joints. Severe distortion was observed in the T1W HBW_TSE image, obstructing the visualization of the thecal sac. O-MAR* shows a significant reduction of the distortions while O-MAR XD* showed a better distortion-corrected image enabling a more accurate appreciation of the anatomy.





Scanning patients with orthopedic implants

When a patient with an orthopedic implant needs an MR scan, the safety label of the implant must be checked. An implant can be labeled “MR Safe,” “MR Conditional” or “MR Unsafe.”¹⁰ An MR Safe implant poses no known hazards resulting from exposure to any MR environment. MR Safe implants are composed of materials that are electrically nonconductive, nonmetallic, and nonmagnetic. An “MR Conditional” implant demonstrated safety in the MR environment within defined conditions. At a minimum, address the conditions of the static magnetic field, the switched gradient magnetic field and the radiofrequency fields. Additional conditions, including specific configurations of the item, may be required. An “MR Unsafe” implant poses unacceptable risks to the patient, medical staff or other persons within the MR environment. Most modern orthopedic implants fall in the category “MR conditional.” Therefore it is the responsibility of the MR staff to check the safety conditions of a patient’s implant and make the MR system adhere to the conditions throughout the whole MR examination.

Philips has simplified the scanning of patients with MR Conditional implants by introducing ScanWise Implant¹¹, the industry’s first MR user interface with guidance that allows the user to enter the implant manufacturer’s condition only once and not scan-by-scan. All scan parameters are automatically adjusted to meet the implant safety condition values entered by the operator and ScanWise Implant makes the MR system adhere to the conditions throughout the whole examination.

Summary

Patients with MR Conditional orthopedic implants can be challenging to scan because of the substantial image artifacts caused by the metal components of the implants. Signal loss caused by field inhomogeneities around metal can be corrected to a certain extent by the use of TSE sequences, and some distortions can be reduced by the choice of scanning parameters such as high bandwidth and thinner slices. However, these measures are very often not sufficient to allow for peri-prosthetic tissue visualization. Metal-induced field inhomogeneities cannot be accurately modeled which is why distortion-corrected MRI near metallic implants should rely, on robust spatial encoding techniques such as O-MAR* and O-MAR XD*.

O-MAR* extends MARS with the VAT technique to improve in-plane distortion correction while O-MAR XD* extends O-MAR* by combining VAT with SEMAC techniques to provide efficient in-plane and through-plane susceptibility artifact correction in the vicinity of metal implants. Diagnostic images of the near-metal bone and soft tissue can be obtained with all relevant image contrasts (T1W, T2W, PDW and STIR) on both 1.5T and 3.0T. O-MAR* and O-MAR XD* enable MR imaging of post-operated patients with MR Conditional implants who could develop several implant related indications such as osteolysis, metallosis, pseudo-tumors and fluid collections.

Orthopedic implants have metal components and therefore are safe to scan only in specified conditions. It is the responsibility of the MR staff to find the conditions defined by the implant manufacturer and make their MR scanner adhere to these conditions for every scan throughout the whole exam. Philips introduced ScanWise Implant to simplify the procedure of entering these conditions. ScanWise implant allows the user to enter the condition values as specified by the implant manufacturer. These values are entered only once and not scan by scan. ScanWise Implant automatically adjusts all scan and pre-scan parameters of all sequences during the whole examination.

With ScanWise Implant and O-MAR XD*, Philips offers a premium** distortion correction solution for MR imaging in the vicinity of an orthopedic implant.

* Only for use with MR Safe or MR Conditional Implants by strictly following the Instructions For Use.
 ** Premium distortion correction defined as O-MAR XD* compared to conventional Philips TSE imaging techniques for reduction of susceptibility artifacts caused by the presence of metal.

References

1. Kurtz, S., et al., Projections of primary and revision hip and knee arthroplasty in the United States from 2005 to 2030. *J Bone Joint Surg Am*, 2007. (4): p. 780-785.
2. Ulrike Dapunt et al, HYPERLINK "/pmc/articles/PMC3994416/"On the inflammatory response in metal-on-metal implants , *J Transl Med*. 2014; 12: 74.
3. B.A. Hargreaves, P. W. Worters, K.B. Pauly, J.M.Koch and G.E. Gold, Metal-Induced artifacts in MRI, *AJR*: 197, sept 2011.
4. L.M. White, J.K. Kim, M. Mehta, N. Merchant, M.E. Schweitzer, W.B. Morrison, C.R. Hutchinson, A.E. Gross. Complications of total hip arthroplasty: MR imaging—initial experience. *Radiology*. 2000;215:254-62.
5. J.E. Vandevenne, F.M. Vanhoenacker, P.M. Parizel, K. Butts, J.M. Pauly, R.K. Lang. Reduction of metal artefacts in musculoskeletal MR imaging, *JBR-BTR*. 2007 Sep-Oct;90(5):345-9.
6. R.V. Olsen, P.L. Munk, M.J. Lee, et al.: Metal artifact reduction sequence: early clinical applications. *Radiographics*, 2000, 20: 699-712.
7. K. Butts, J.M. Pauly, G.E. Gold: Reduction of blurring in view angle tilting MRI. *Magn Reson Med*, 2005, 53: 418-424.
8. W. Lu, K.B. Pauly, G.E. Gold, J.M. Pauly, B.A. Hargreaves. SEMAC: Slice encoding for metal artifact correction in MRI. *Magn Reson Med* 2009;62(1):66-76.
9. F. Traina, M. De Fine, A. Di Martino, and C. Faldini. Fracture of ceramic bearing surfaces following total hip replacement: A systematic review *BioMed research International Volume 2013*, Article ID 157247.
10. ASMT F2503-13, Standard practice for marking medical devices and other items for safety in Magnetic Resonance environment, ASMT International, West Conshohocken, PA, 2013, www.asmt.org.
11. Johan van den Brink et al, Simplify scanning of patients with MR Conditional implants, <https://www.usa.philips.com/b-dam/b2bhc/master/events/ISMRM2016/philips-scanwise-implant-whitepaper.pdf>

