

*Original Article***Middle Ear Implants: Historical  
and futuristic perspective**

Guyan Andre Channer MD, Adrien A Eshraghi MD, LIU Xue -zhong MD, PhD

*Department of Otolaryngology, University of Miami, Miami, Florida, USA*

**Abstract** Technological advancements are continuously changing the paradigm of human existence. Human beings are constantly engaging in various measures to reduce the extent of sensory and motor impairment. This has been in the form of various devices, e.g. orthopedic prosthesis, visual aids (spectacles) and hearing aids. Countless attempts throughout the centuries have been made in an effort to improve sound amplification in patients. This article seeks to highlight the technological journey of one such implant, the middle ear implant, from its inception to the more technological advanced futuristic proposals. While there are many amplification devices available presently, there still remains a group of patients who have not experienced adequate amplification for their hearing loss and this subset may gain the greatest benefit from middle ear implants.

**Keywords** middle ear implants, vibrant sound bridge, esteem envoy, Rion E device, hearing aids, Totally Implantable Cochlear Amplifier, middle ear transducer (MET), MAXUM

**Introduction**

Hearing loss affects a significant portion of any population with increasing prevalence with age. It has been estimated that up to 15% of patients over the age of sixty five years old have clinically significant hearing loss.<sup>11</sup> The management is highly dependent on the type (i.e. sensory-neural vs. conductive) and degree (i.e. mild, moderate, severe or profound) of hearing loss. Profound hearing loss rehabilitative options mainly include cochlear implants and brain stem implants. Traditionally, conventional hearing aids (CHA) have been the mainstay of auditory rehabilitation for patients with mild to severe hearing loss. Wide arrays of CHA are available for usage. The designs and rehabilitative potential are constantly undergoing improvement. Designs for the microphone and processor unit include several models; behind the ear (BTE), in the canal (ITC) and completely in the canal (CIC). The speaker may have a close or an open design. The latter aims to reduce the occlusion effect experienced with closed speaker designs. Unfortunately approximately 15–20% of patients with CHA are inconsistent users.

Some commonly reported problems may be encountered however. These include an occlusion effect, auditory feedback, constant irritation, infection and cosmetic effect.

The occlusion effect is observed due to the presence of the CHA in the external ear canal which gives the sensation of ear congestion/occlusion. Feedback arises due to the close proximity of the speaker to the microphone on the CHA. Patients may also suffer from constant irritation and infection of the ear canal which reduces compliance of the device use. It is reported that despite the advances in CHA, there remains 10–20% of the hearing loss population who derives inadequate benefit from CHAs.<sup>17</sup> The advent of middle ear implants promises to reduce these common flaws in the CHA and offer a similar or superior means of hearing rehabilitation.

**Historical Background**

The concept of middle ear implant was born from the idea to have sound amplification and transmission mechanically rather than via sound waves. This idea was first conceptualized by Finnish scientist Alvar Wilska (1911–1987). He conducted experiments by placing iron particles on the tympanic membrane. He induced vibration of these particles by placing an electromagnetic coil inside an earphone which he placed within the ear. In an attempt to promote his theories, he actually

---

*Corresponding author:* Dr. Xue Zhong Liu Department of Otolaryngology (D-48) University of Miami 1666 NW 12<sup>th</sup> Avenue Miami, Florida 33136, USAE-mail: xliu@med.Miami.edu Tel: 305 243 5695; Fax: 305 243 4925

conducted some of these experiments on himself. He presented a brilliant thesis on the directionality of hearing.<sup>1</sup> His theories were not readily accepted initially however and his disappointment drove him to direct his research elsewhere. He became an important figure in the development of photography and the electron microscope.

After Alvar Wilska's initial experiments, the field of MEI experienced a dormancy of ideas for several decades. Rutschmann resumed experiments in 1959. This was similar to Wilska's in that he glued 10 mg magnets unto the tympanic membrane in the presence of alternating magnetic fields in the canal. This resulted in successful stimulation of the ossicles. It wasn't until late 1970's however before actual implants were placed in the middle ear, conducted by Goode (1970), Fredrickson (1973) and Nunelly (1976).

### **Characteristics of MEI**

Middle ear implants (MEI) are actually transducers. They can be categorized based on whether the device is totally or fully implantable or based on the type of transducer utilized by the device.

They utilize two main transducers. These are electromagnetic and piezoelectric.<sup>15</sup>

Electromagnetic devices were the first elements utilized and account for majority of MEI in circulation. The principle of the electromagnetic MEI is that a magnet placed in an electric field induces a constant, reproducible, predictable directional force. A microphone consists of a magnet in an electric field. The sound energy is converted to electric energy which undergoes amplification and the amplified product is sent to a generator which induces movement along the ossicular chain. The advantages of the electromagnetic transducers are that it allows for greater gain and output. The disadvantages however are that it has more power consumption (20–30 times) and it is physically bulkier than the piezoelectric transducers.

The piezoelectric transducers are based on the principle that a constant deformational change can be consistently induced relative to a voltage input and vice-versa. This deformation results in displacement of the ossicular chain. There are two types of piezoelectric transducers. These are crystals (e.g. quartz) and ceramic (lead zirconate titanate). Two conformation forms exist for piezoelectric devices, monomorph and bimorph. The

monomorph utilize a single component that directly provides the displacement with input voltage. The bimorph device consists of two components fixed to each other with opposite polarities. The piezoelectric transducers have the advantage of being smaller, less bulky and using less power than their counterpart electromagnetic transducers. Piezoelectric transducers are also utilized in other areas of daily living including airbags, clocks and electric guitars.

A wide array of MEI devices have been produced over the years with the majority no longer being utilized. These include

1. Rion E device
2. Totally Implantable Cochlear Amplifier (TICA)
3. Maniglia device
4. Heide device
5. SOUNDTEC

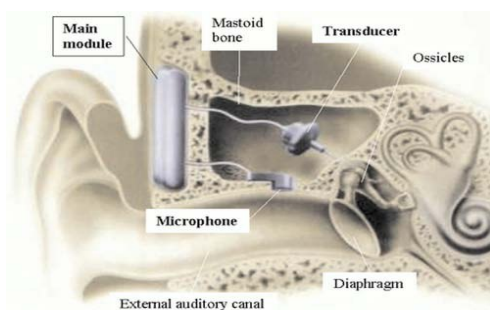
### **Rion E device**

The first commercially available MEI was developed by Yanagihara and Suzuki at Ehime and Teikyo Universities in Japan in 1984. It was a partially implantable device using the piezoelectric transducer. It was coined the Rion E device.<sup>19</sup> The external component consisted of a primary induction coil, microphone amplifier and a battery compartment. The internal component consisted of a secondary coil which was fixed to the lateral surface of the squamous portion of the temporal bone. This was electrically connected to a piezoelectric transducer located in the mastoid cavity which served as the ossicular vibrator fixed to the capitulum of the stapes. Surgical implantation required a modified radical mastoidectomy with removal of the malleus, incus and the tympanic membrane. The ear canal was closed. As technological advancements improved, Yanagihara improved the design to accommodate the new technology but the surgery and implantation technique remained the same. Yanagihara reviewed his long term results in 2001 and identified that only ten of twenty-seven (10/27) patients had stopped using their first design implant at the ten year mark and nine out of eleven (9/11) patients were using the second design implant at the ten year mark. He identified complications of fistula, cholesteatoma etc. There was a hearing increase of 36 dB that dropped to 21 dB in his 10 year review which he attributed to aging and tissue reaction to the device. Since this review the device has largely fallen out of

favor.<sup>19</sup>

### **Totally Implantable Cochlear Amplifier (TICA)**

The concept of a totally implantable device is attractive as it offers improved cosmetic appearance and an ability to utilize amplification in wet environment (e.g. while swimming). The first commercially developed totally implantable device was developed in Germany. The basic concept of the device was developed by Leysieffer and Zenner, between 1990 and 1992 at the University of Tübingen, Germany. It was coined the totally implantable cochlear amplifier (TICA). It was originally produced by Implex American Hearing Systems which was taken over by Cochlear Corporation in Sydney, Australia. It consists of a microphone, a main module housing the rechargeable battery and amplifier and an actuator. It has a piezoelectric heteromorph transducer with a ceramic base (see figure 1). The battery has a five year expected life time and can be used for 50 hours after being charged for two hours using a hand held device. An initial temporal bone study by Maasen et al confirmed the feasibility in humans.<sup>13</sup> The device first gained popularity in Europe and obtained CE approval in 1999. It is CE certified for patients with moderate to severe high-frequency SNHL. A clinical trial by Zenner and Rodriguez advocates for TICA approval in patients who fulfill the following three selection criteria.<sup>20</sup> These include lack of benefit from conventional hearing aids, moderate to severe high-frequency SNHL and adequate space in the mastoid for implantation.



**Figure 1** Totally integrated cochlear amplifier. (Source: Dammann F, et al. Radiographics 2001;21:183–190) Used by permission."

The objective of the TICA was to utilize the patients' basic anatomy as much as possible. The surgical approach involves a simple mastoidectomy with fixation of the main module to the lateral squamous surface of the temporal bone. Bone is gently removed from a small area in the posterior bony external ear canal wall. This

is done to facilitate the microphone placement. Electrical impulses from the microphone are relayed to the main module where amplification takes place to finally be transmitted to the actuator which houses the piezoelectric transducer. This actuator is then coupled to the body of the incus. This concept was designed to utilize the natural pathway of the ear canal being the initial conduit for sound without the physical presence of the device in the canal which contributes to the occlusion effect and the other disadvantages of the CHA. Initially a problem in design was noted however as the coupled actuator–incus would not just allow for anterograde transmission to the stapes and cochlear but also would allow for retrograde transmission to the malleus, tympanic membrane and eventually back out through the ear canal. The main drawback was that the microphone sensor would sense these transmitted sounds resulting in feedback similar to the CHA design. To overcome this hurdle, a reversible malleus neck dissection (RMND) was done simultaneously to prevent retrograde transmission.

The device was marketed by Implex which eventually went out of business. It was purchased by cochlear corporation but the device has not been re-introduced to the market. The disadvantages of the device were highlighted in a review. These included an insufficient output, negative effect on residual hearing and negative feedback. It has not been FDA approved in the United States of America (USA) as a result.

### **Maniglia device**

The use of the electromagnetic device once again gained favor and was reintroduced by Maniglia et al.<sup>14</sup> Their development began in Cleveland, USA at Case Western Reserve University. The device was semi-implantable consisting of an external and an internal component. The external component housed the microphone, battery and amplifier. The internal component contained the internal coil which was affixed to the lateral squamous temporal bone similar to the TICA and Rion E devices. This was connected to the electromagnetic transducer. The concept was to implant an electromagnetic device to the body of the incus to induce vibrations. To facilitate this, a dentistry approved adhesive, metabond, was used to glue the neodymium magnet to the body of the incus. Surgical implantation required a simple mastoidectomy with exposure of the ossicles in the epitympanum. The advantages of the device are that the ossic-

ular chain and ear canal remain undisturbed and that the battery being external would not require surgery to facilitate replacement. The device went to clinical trial but only one patient entered the trial. There was also a problem noted with power output. The device was subsequently withdrawn from the market.

### **Heide device**

Heide et al first published the design for semi-implantable hearing aids in 1988.<sup>6</sup> The device was developed for patients with ossicular pathology. It utilized an external and an internal component. The external component (magnetic driver) consisted of a removable ear canal device similar to CHA. This device housed a sensor, an amplifier and a electromagnetic coil. The internal component was the ossicular replacement prosthetic device which was magnetized. The concept was similar to that proposed by Wilska in that if a magnetic field could be established in the ear canal (EAC), it could induce amplified but similar movement of a metallic object affixed to the ear drum and result in sound propagation. Kartush and Tos from Michigan Ear Institute implanted the first nine patients with the device in a FDA-approved study in 1991 and coined them the "first generation SIM aids".<sup>10</sup> These patients all had ossicular chain pathology. In a retrospective review, it was revealed that six of the original nine (6/9) patients were still using the device (4 total ossicular replacement prosthesis (TORPs) + 2 partial ossicular replacement prosthesis (PORPs)) after 9.5 years. A functional gain of as much as 40 to 70 dB for the entire frequency range of the audiogram was noted with superiority over CHA noted especially in the high frequencies. Four patients had experienced 10–30 dB deterioration of hearing.<sup>3</sup> The reported disadvantages of the device were that the magnetic driver was too tight and had an occlusion effect similar to CHA, predisposition to irritation and infection similar to CHAs and that any shift of the magnetic driver in the EAC resulted in suboptimal hearing. The prosthesis was thought to be rather thick with large diameter and the edges were too sharp which could result in extrusion. In the end they too concluded the device was disappointing and the company withdrew their support.

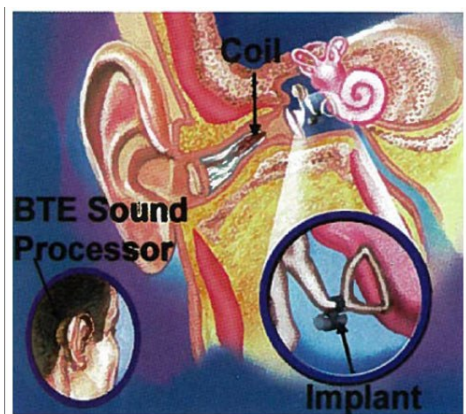
### **Soundtec**

This was a similar concept to the Heide device. It was the brainchild of Hough et al and was coined the direct

drive hearing system (DDHS) and later known as the SOUNDTEC device (see figure 2).<sup>7</sup> The external component comprised of the sensor, electromagnetic transducer and amplifier. The internal component comprised of neodymium iron boron magnet initially which degraded over three 3 months wearing time. This was replaced by a Samarian cobalt magnet. The external component was placed within the ear canal similar to a CHA. The internal component was surgically placed on the capitulum of the stapes and required simultaneous separation of the incudo-stapedial joint. The initial study was encouraging and was conducted in guinea pigs in which the ABR was measured. It was subsequently conducted in patients undergoing surgery for otosclerosis and chronic tympanic membrane perforation. A review was conducted by Silverstein et al.<sup>16</sup> They conducted a retrospective review of 64 patients. there was an average functional gain of 26 dB across all frequencies. The main complaint in 55% of patients was of magnet movement. This resulted in suboptimal and varying results. Several options were utilized to stabilize the magnet including ear lobe fat, tragal cartilage, bone pate, and tissue seal. There was an eighty percent (80%) improvement in suboptimal performance when an external processor is used and fat utilized to stabilize the magnet. It was also noted that when the neodymium iron boron magnet was replaced with Samarian cobalt magnet, this resulted in damping as the Samarian cobalt was larger than the boron magnet. Implantation could be done under local anaesthesia and involved a transcanal approach similar to that for stapes surgery where a posterior tympanomeatal flap was elevated and the device placed on the stapes capitulum after separation of the incudo-stapedial joint. The disadvantages of the device included the need for disruption of the ossicular chain (separation of the incudo-stapedial joint) and the presence of the device in the EAC resulting in an occlusion effect, etc. The advantages included no need for mastoidectomy, procedure being as an office procedure under local anaesthetic and potentially reversible ossicular disruption with application of bone cement at the ISJ. The device was subsequently withdrawn in 2004 by the company.

Since the advent of these early devices, other MEI have been developed which are available for patient use. These include

1. MAXUM
2. Vibrant soundbridge
3. MET
4. ESTEEM ENVOY



**Figure 2** Sound Tec Electromagnetic Device"(c) Otologics LLC. Used by permission."

### **Maxum**

In 2009 the SOUNDTEC device had a resurgence when the company was bought by Ototronix and the device renamed "MAXUM". The changes included a conversion to a fully digitalized system, a change of the magnetic canister to titanium and the separation of the ISJ was no longer required. The external component had two main designs. One design had the integrated processor and transceiver as a compact single unit completely in the canal (CIC). The second design had the processor behind the ear (BTE) which was connected to the transceiver within the canal. The internal device remained at the ISJ and there was no need for ISJ separation. The procedure could still be performed as an outpatient procedure under local anesthesia and there was no need for mastoidectomy. The device was approved by the US Food and Drug Administration (US FDA). The designers proposed a functional gain of 7.0–7.9 dB PTA gain over CHA in the low frequencies and 9.2–10.8 dB PTA gain over CHA in the high frequencies. The approval suggests that it is indicated in adults with moderate to severe sensori–neural hearing loss. They also suggest contraindications in conductive hearing loss, retro–cochlear or central auditory disorder, active middle ear infections, and tympanic membrane perforations associated with recurrent middle ear infections and disabling tinnitus. The potential advantages and disadvantages are potentially similar to the SOUNDTEC device. The advantages included no need

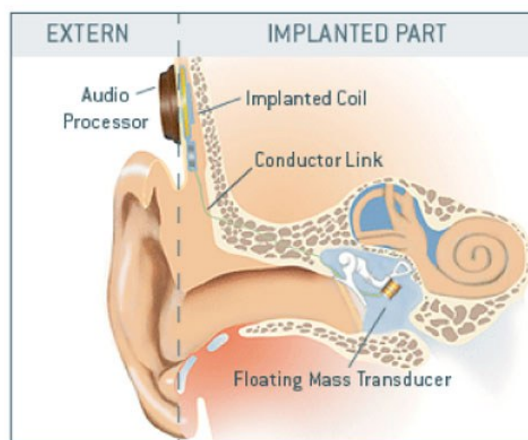
for mastoidectomy with its potential risks of facial nerve injury etc. and that the procedure being an office procedure under local anaesthetic. The disadvantages included the need for disruption of the ossicular chain (separation of the incudo–stapedial joint) which resulted in a maximum conductive hearing loss in unaided conditions and also that the presence of the device in the EAC resulted in an occlusion effect and other disadvantages similar to CHA.

### **Vibrant Sound Bridge (VSB)**

The vibrant sound bridge (VSB) device was developed by Ball in 1996 and marketed by Symphonix devices (San Jose, Ca). It obtained European CE approval in 1998 and US FDA approval in 2000. The company was subsequently acquired by Vibrant Med–El (Med–El Corporation, Austria) in 2003.

The device is a semi–implantable device. (See figure 3). It utilizes an electromagnetic design in a "floating mass transducer" (FMT). The internal component consists of two primary components: the Vibrating Ossicular Prosthesis (VORP) and the Audio Processor (AP) which are connected via a conductor link. The external component consists of a battery compartment designed as a BTE along with a sound processor, microphone and a transmitter system similar to a cochlear implant design. The floating mass transducer was originally designed to be connected to the long process of the incus via a titanium attachment and to the audio processor via a conductor link. While being attached to the long process of the incus, the body of the FMT is surgically positioned to be perpendicular to it and parallel to the capitulum of the stapes so that the generated movement is along the axis of the axis and produces as physiological a result as possible. Several modifications have arisen to the placement of the FMT.<sup>4</sup> These include direct placement on to the capitulum of the stapes as a PORP, direct placement on to the stapes footplate as a TORP or direct placement on to the round window. These approaches are especially useful in patients with congenital or acquired loss of the ossicular chain (e.g. due to cholesteatoma). Surgical placement requires a cortical mastoidectomy with exposure of the facial recess from which the mesotympanic structures can be seen. If there is already loss of the incus, an extended facial recess superiorly can allow for added exposure. The internal receiver is placed just beneath

the skin and is usually fixated by drilling a bony well and suture ligated onto the bone. The FMT is then placed appropriately via the facial recess to the area of choice based on the anatomy. Truy et al also proposed an additional approach, a transcanal approach, which would negate the need for a formal mastoidectomy (with reduced risk to facial nerve and inner ear structures).<sup>18</sup> They noted no significant difference in surgical morbidity (except for dysguesia) and that the transcanal approach was easier and faster. The disadvantages of the transcanal approach include the unfamiliarity of the technique by many surgeons, the risk of device extrusion and otitis externa.



**Figure 3** Med-EL Vibrant Soundbridge Electromagnetic Device"(c) Otologics LLC. Used by permission."

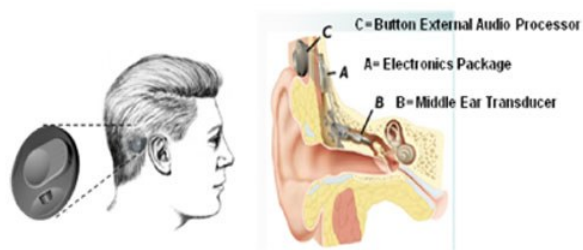
A phase three multicenter trial was carried out in the US. Luetje et al reported on a prospective controlled multicenter study with 53 patients.<sup>12</sup> Inclusion criteria consisted of adults (<18 years), SDS > 50% and sensori-neural (SNHL) only and the worse ear was to be implanted. Improvements in satisfaction, performance, and preference were statistically significant with the VSB, as was functional gain across all test frequencies ( $P < 0.001$ ). It was noted that occlusion and feedback were virtually eliminated. Aided speech recognition was comparable between VSB and the hearing aid and residual hearing was unchanged. There were also reported improvements in overall sound quality, clearness of sound and tone, and improved sound quality with respect to their own voice. There was statistically significant functional gain noted over the CHA in all frequency ranges. There was improvement in hearing in all scenarios with the VSB except in the use of the

telephone. Another finding suggested no long term deterioration with the device. In 2010, Cremers reported on an international consensus regarding paediatric VSB implantation.<sup>5</sup> They agreed that "The Vibrant Soundbridge is appropriate for application in subjects under age 18 when the subject satisfies the inclusion criteria, including having adequate anatomy to allow placement of the VSB and when weighed against and compared to other potential therapies." The proposed inclusion criteria for the pediatric patient were patients with an ear anatomy that can facilitate positioning of the FMT in contact with a suitable vibratory structure of within the ear, patients with SNHL who presently uses a hearing aid for at least four hours per day prior to evaluation or shall not be able to wear or benefit from conventional hearing aids for medical reasons or any patient who is psychologically and emotionally stable with realistic expectations of the benefits and limitations of the VSB.

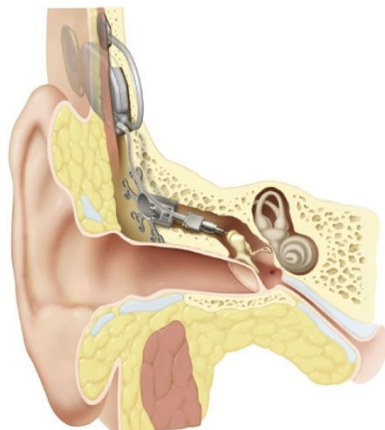
The overall advantages of the device are mentioned above but also include the ability to upgrade the external processor and to change the batteries without the need for surgery. The disadvantages include the need for general anesthesia, mastoidectomy and the potential risks of facial nerve injury and hearing loss.

### Otologics

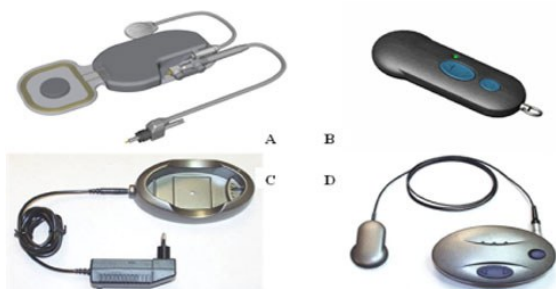
The Otologics implant was originally developed by Fredrickson at Washington University in St Louis, USA. It originally consisted of a semi-implantable electromechanical device utilizing a middle ear transducer (MET). (See figure 4). It gained European CE mark in 2001. Jenkins et al reported on a clinical trial which demonstrated that the device was safe, that there was no significant change in hearing threshold and that it surpassed the functional gain of CHA.<sup>8</sup> Shortly after, the fully implantable device was developed. This was coined the CARINA or Fully Implantable Ossicular Stimulator (FIMOS). (See figure 5 and 6). This new device gained European CE mark in 2006. The semi-implantable device was initially submitted for US FDA approval but this was withdrawn and a subsequent approval for the fully implantable device submitted. Presently, pre-approval clinical trials are being done in the USA.



**Figure 4** Otologics Semi-Implantable Device"(c) Otologics LLC. Used by permission."

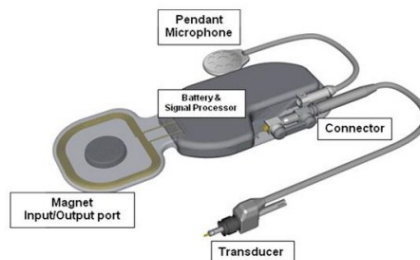


**Figure 5** Otologics MET Fully Implantable Middle Ear Device" (c) Otologics LLC. Used by permission."



**Figure 6** (A) (B) (C) (D). Components of the Otologics MET Fully Implantable Device The Otologics MET Fully Implantable Ossicular Stimulator consists of three primary components: the implant (Figure 6A), the remote control (Figure 6B) and the charger (Figure 6 C/D)"(c) Otologics LLC. Used by permission."

The fully implantable device comprises of a main magnet input/output port, battery and signal processor. (See figure 7). This communicates with the pendant microphone and transducer via a connector. This transducer houses the electromechanical device and is connected to the body of the incus whilst the remainder of the device lies in a subcutaneous plane posterior and superior to the pinna.



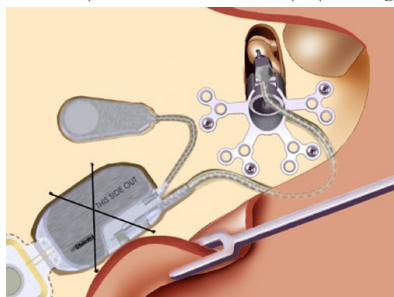
**Figure 7** Magnet, input/output port, battery and signal processor, transducer, and microphone"(c) Otologics LLC. Used by permission."

The technique for surgical implantation of this device differs slightly from the technique for other MEIs that require a cortical mastoidectomy. The approach is similar with a post-auricular incision but the mastoidectomy is limited. (See figure 8). Drilling commences just inferior to the superior temporal line for approximately six (6) mm. the principle is early identification of the spine of Henle and subsequently the aditus ad antrum and the incus. Theoretically, this negates the need for a routine cortical mastoidectomy and facial recess approach which places the facial and chorda tympani nerves at risk. Drilling proceeds medially until the body of the incus is identified. Using a micro-drill or laser, a pinpoint hole is carefully made into the body of the incus postero-laterally with care taken not to disarticulate the ossicular chain. The main internal component is placed into a bony well recess with tie-down sutures. The transducer is placed via the carefully drilled tunnel into the aperture created in the body of the incus with the device being fixed to the overlying cortical bone with pre-designed plates. This can be technically difficult however and requires prior special training.

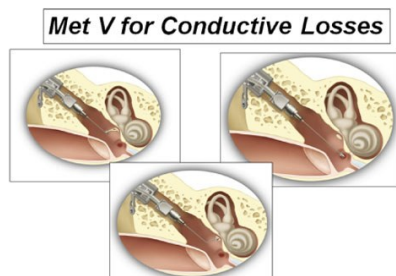
The device can be charged via an external component which is placed over the magnet and charging done trans-cutaneously. It can also be fitted with a handheld remote control that adjusts the degree of amplification.

In the US, Jenkins et al reported on phase 1 preliminary results of use of the Otologics MET Fully-Implantable Ossicular Stimulator.<sup>9</sup> Twenty patients were included in the study. There was no noted change in residual hearing threshold. The device achieved 10–20 dB increase in functional gain across audiometric frequencies which are greater than semi-implantable device with less frequency variability. Group mean statistics,

however, showed significance ( $p=0.035$ ) for static compliance changes. Peri-operative problems included fullness or pressure sensation,<sup>2</sup> conductive hearing loss,<sup>4</sup> lightheadedness,<sup>1</sup> tinnitus,<sup>1</sup> partial device extrusion<sup>3</sup> (requiring skin grafting) and middle ear effusion.<sup>3</sup> Problems encountered by subjects included inability to charge or establish communication<sup>2</sup>, elevated thresholds<sup>1</sup> and increased charging times beyond 1.5 hours.<sup>7</sup> Adaptations for the device include MET V which has been modeled for conductive hearing loss patients and especially with patients with congenital or acquired ossicular chain disruption. In this model, the transducer tip has been modified to allow for direct fitting unto the stapes capitulum, the stapes footplate as well as the round window (similar to the VSB). (See figure 9).



**Figure 8** Post surgical drilling of the bone bed and thinning of the flap"(c) Otologics LLC. Used by permission."



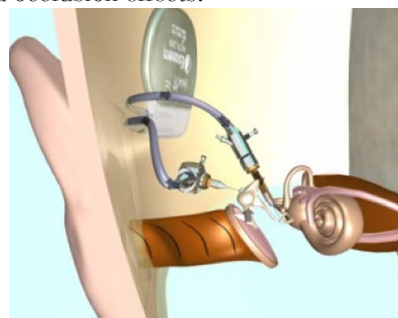
**Figure 9** The Otologics Fully Implantable MET - V conductive/mixed hearing loss application"(c) Otologics LLC. Used by permission."

The advantages of this device are preservation of the intact ossicular chain remains, reduced risk to facial nerve injury during limited mastoidectomy and the utilization of the natural middle ear mechanism. The disadvantages include the technically challenging surgery and the potential for ossicular chain disruption.

### **Esteem**

Another fully implantable device was developed and distributed by St Croix Medical. It was originally coined Envoy but eventually the name of Esteem was chosen. (See figure 10). The concept was similar to the TICA

originally developed by Leysieffer and Zenner. The device consists of two piezoelectric transducers. It also has a sensor which detects movement of the incus and this is transmitted to the sound processor which is located in the recesses of the mastoid bone. Electrical impulses are sent from the processor to the piezo-electric device which is attached to and transmits mechanical movement to the capitulum of the stapes. This concept is appealing as it utilizes the natural pathway for sound along the ear canal, tympanic membrane and to the ossicles. The principles of the standing wave and the amplification effect of the pinna are thus utilized. It does not utilize a microphone or a canal component which reduces the risk of problem associated with CHA including feedback and occlusion effects.



**Figure 10** Esteem Peizeolectric Device"(c) Otologics LLC. Used by permission."

Surgical implantation requires a cortical mastoidectomy and facial recess approach similar to other MEI devices. A bony recess is drilled and the processor fixed with suture ties. The sensor is connected to and senses vibrations from the body of the incus. The generated electrical energy is transmitted back to the processor which is recessed in the bone. The processor amplifies the energy input and transmits the amplified product to the driver which is connected to the capitulum of the stapes. The surgery requires a resection of the long process of the incus (ossicular discontinuity) to prevent dampening of the vibration. The advantages of this device and technique are that the ossicular chain mechanism is utilized, that there is no need for microphone negating the potential for feedback and that the device can be utilized in wet conditions (e.g. while showering).

Barbara et al reviewed the preliminary results for the device and concluded that the disadvantages included the need for mastoidectomy, the need for removal of the long process of the incus which resulted in reduced



thresholds when device is not in effect (worsened unaided residual hearing; maximum conductive hearing loss), the need for non-rechargeable lithium battery requiring (3–5 year) replacement and that surgery was complex involving cementing the device to two ossicles and ensuring adequate space and positioning.<sup>2</sup>

A new model, the Esteem II has been developed and proposes to have a newer longer lasting battery (5–8 years) with technological improvement.

### Conclusion

The role of the middle ear implant is constantly evolving. There is a thrust towards fully implantable device but notwithstanding: the benefits of a partially implantable device are significant. The indications for the devices are also being altered by the technological advances in conventional hearing aids and other devices, e.g. cochlear implant. Another potential future role is to have the device technologically linked with other devices e.g. cochlear implant hybrid device. An absolute role of middle ear implant is being questioned but it undoubtedly remains a viable option for patients with mixed or sensorineural hearing loss, especially for those patients in whom conventional hearing aids are undesirable (due to recurrent ear infection) or offer limited benefit.

### References

- 1 .Alvar Wilska. Studies on Directional Hearing. Doctoral thesis. Acta Societatis Medicorum Fennicae” Duodecim” Ser. A, Tom. XXI, Fasc. 1. Helsinki, 1938
- 2 Barbara M, Biagini M, Monini S. The totally implantable middle ear device ‘Esteem’ for rehabilitation of severe sensorineural hearing loss. Acta Otolaryngol. 2011,131(4): 399–404.
- 3 Cayé–Thomassen P, Jensen JH, Bonding P, et al. Long-term results and experience with the first-generation semi-implantable electromagnetic hearing aid with ossicular replacement device for mixed hearing loss. Otol Neurotol. 2002,23(6): 904–11.
- 4 Cremers, C. W., Verhaegen, V. J., & Snik, A. F. (2009). The floating mass transducer of the Vibrant Soundbridge interposed between the stapes and tympanic membrane after incus necrosis. Otology & Neurotology, 30, 76–78
- 5 Cremers CW, O’Connor AF, Helms J, et al. International consensus on Vibrant Soundbridge® implantation in children and adolescents. Int J Pediatr Otorhinolaryngol. 2010, 74(11):1267–9.
- 6 Heide J, Tatge G, Sander T, et al. Advances in audiology, Vol 4: Middle ear implant: Implantable hearing aids. In Hoke M, ed. Development of a semi-implantable hearing device. Basel: Karger, 1988
- 7 Hough JV, Dyer RK Jr, Matthews P, et al. Early clinical results: SOUNDTEC implantable hearing device phase II study. Laryngoscope. 2001 , 111(1):1–8.
- 8 Jenkins HA, Niparko JK, Slaterry WH, et al. Otologics Middle Ear Transducer Ossicular Stimulator: performance results with varying degrees of sensorineural hearing loss. Acta Otolaryngol. 2004 , 124(4):391–4.
- 9 Jenkins HA, Atkins JS, Horlbeck D, et al. U.S. Phase I preliminary results of use of the Otologics MET Fully-Implantable Ossicular Stimulator. Otolaryngol Head Neck Surg. 2007, 137(2):206–12.
- 10 Kartush JM, Tos M. Electromagnetic ossicular augmentation device. Otolaryngol Clin North Am. 1995 , 28(1):155–72.
- 11 Kochkin, S. (2005). MarkeTrak VII: Hearing loss population top 31 million people. Hearing Review, 12(7), 16–29.
- 12 Luetje CM, Brackman D, Balkany TJ, et al. Phase III clinical trial results with the Vibrant Soundbridge implantable middle ear hearing device: a prospective controlled multi-center study. Otolaryngol Head Neck Surg. 2002, 126(2): 97–107.
- 13 Maassen MM, Schwaderer E, Heinrich B, et al. Comparison of the implantability of electronic hearing devices in a virtual–reality planning environment and human temporal bones. Acta Otolaryngol 2004; 124:1–7.
- 14 Maniglia AJ, Ko WH, Garverick SL, et al. Semi-implantable middle ear electromagnetic hearing device for sensorineural hearing loss. Ear Nose Throat J. 1997 , 76(5):333–8, 340–1.
- 15 Park IY, Shimizu Y, O’Connor KN, et al. Comparisons of electromagnetic and piezoelectric floating–mass transducers in human cadaveric temporal bones. Hear Res. 2011 , 272 (1–2):187–92.
- 16 Silverstein H, Atkins J, Thompson JH Jr, et al. Experience with the SOUNDTEC implantable hearing aid. Otol Neurotol. 2005 ,26(2):211–7.
- 17 Sprinzl GM, Riechelmann H. Current trends in treating hearing loss in elderly people: a review of the technology and treatment options – a mini-review. Gerontology. 2010, 56(3):351–8.
- 18 Truy E, Eshraghi AA, Balkany TJ, et al. Vibrant sound-bridge surgery: evaluation of transcanal surgical approaches. Otol Neurotol. 2006 , 27(6):887–95.
- 19 Yanagihara N, Sato H, Hinohira Y, et al. Long-term results using a piezoelectric semi-implantable middle ear hearing device: the Rion Device E-type. Otolaryngol Clin North Am. 2001,34(2):389–400.
- 20 Zenner HP, Rodriguez Jorge J. Totally Implantable Active Middle Ear Implants: Ten Years’ Experience at the University of Tübingen. Böheim K (ed): Active Middle Ear Implants. Adv Otorhinolaryngol. Basel, Karger, 2010, vol 69, pp 72–84

(Received October 15, 2011)