

Magnetic Eyelashes: A New Source of MRI Artifacts

Einat Slonimsky¹
Alexander Mamourian

OBJECTIVE. The purpose of this study was to show, by use of a phantom, that magnetic eyelashes worn in the MRI environment can cause substantial artifact and that detachment of the eyelashes from the phantom can occur.

CONCLUSION. A new cosmetic product, magnetic eyelashes, should be of interest and concern to radiologists and technologists working in the MRI environment. We strongly recommend inserting a line about magnetic eyelashes on the MRI safety questionnaire and adding stops in the screening system to prevent the entry of anyone with these lashes, including staff, into the MRI scanner room.

MRI has become a routine imaging technique, but the powerful magnets used in MRI scanners, which are often 3 T, or 60,000 times greater than the magnetic field of the earth, provide a source of risk. This powerful attraction creates a projectile risk for the patient and staff when large objects are attracted to the center of the magnet, but smaller ferromagnetic objects are still a problem because they may degrade image quality or, when attracted into the magnet bore, alter the homogeneous magnetic field.

For that reason, all MRI sites have systems in place to screen patients so that any metallic objects, such as watches and hairpins, are removed before patients enter the magnet room [1]. Although this screening process usually involves patients completing a questionnaire that lists common implants, we report the potential effects and risk of imaging patients who use a relatively new cosmetic product: magnetic eyelashes.

False eyelashes are a growing segment of the cosmetics industry, with sales in the United States having increased by 31% since 2017 [2]. In addition to the usual offerings, a new version uses magnets rather than glue to adhere the false eyelashes to the native lashes. Although our staff had little to no awareness of the existence of magnetic eyelashes, the *Wall Street Journal* reported that instruction on their use and application was the top trending beauty-related search on Google in 2018 [2].

These reusable magnetic eyelashes attach via a pair of thin strips of magnets rather than glue at their base. When properly positioned, these tiny magnets adhere to each other and remain attached to the wearer's own upper lashes.

We used a phantom to address concerns regarding the magnitude of the artifact caused by magnetic eyelashes and the potential for these lashes to detach from the native lashes in the magnet bore, where they could attach themselves to the scanner cowling and become a source of static magnet heterogeneity. We did not attempt to scan a volunteer who was wearing these lashes because of the potential for injury resulting from heating or trauma to the lashes or eyelids if the lashes should detach.

Materials and Methods

We used a water-based phantom to evaluate the properties of magnetic eyelashes in the MRI machine. Our purpose was to evaluate the magnitude of the susceptibility artifacts created by magnetic eyelashes on multiple standard imaging sequences and compare these artifacts with those created by aneurysm clips, which are a common source of image distortion. We indirectly expected to determine the potential of these magnetic lashes to move once the phantom was within the MRI scanner bore.

Two sets of magnetic eyelashes from the same manufacturer that were randomly selected and purchased online were used for this experiment.

The phantom was created by drilling multiple 2-mm holes in a plastic container and then run-

Keywords: artifact, magnetic eyelashes, MRI safety, questionnaire

doi.org/10.2214/AJR.19.21550

Received April 5, 2019; accepted after revision May 10, 2019.

¹Both authors: Department of Radiology, Penn State Health Milton S. Hershey Medical Center, 500 University Dr, Hershey, PA 17033-0850. Address correspondence to E. Slonimsky (einatslow@gmail.com).

AJR 2019; 213:983–985

0361–803X/19/2135–983

© American Roentgen Ray Society

Slonimsky and Mamourian

ning monofilament line through the holes to create a grid. The two sets of eyelashes were attached to single nylon strings placed diagonally within the phantom (Fig. 1). The phantom was then submerged in a container filled with distilled water and then covered with a layer of plastic film to prevent free movement of the lashes if they should detach.

MRI was performed using a 3-T scanner with T2-weighted images (TR/TE, 4500/100), FLAIR images (TR/TE, 800/119; inversion time, 2370 ms), T1-weighted images (TR/TE, 600/6), susceptibility-weighted images (SWI) (TR/TE, 28/20), DW images (TR/TE, 4000/51), T1-weighted magnetization-prepared rapid-acquisition gradient-echo (MPRAGE) images (TR/TE, 1500/2.67; inversion time, 900 ms), and T2-weighted sampling perfection with application-optimized contrasts using different flip-angle evolutions (SPACE) images (TR/TE, 3000/412).

Additional scans were obtained at separate times but with the same scanner. We used the same phantom with three surgical clips attached to the strings (two made of cobalt alloy and one made of titanium) and also used the same scan parameters to compare the size of the aneurysm clip artifacts with those of the magnetic eyelashes. The size of the artifact was measured both on scans of the magnetic eyelashes and on scans of the surgical clips.

Results

The magnetic eyelashes created a large artifact (Fig. 2) that was much larger than that created by the aneurysm clips using the same sequences (Fig. 3). The artifact measured 7 × 6 cm and was maximal on SWI, as was expected, and obscured the entire phantom.

Although the eyelashes stayed attached to the strings during the scan, on removal of the phantom from the bore, one set of eyelashes detached from its string but was

restrained by the plastic covering and became attracted to the other eyelashes still attached to the phantom.

Discussion

The concept of unsafe MRI is a continually moving target. Devices that were never scanned with MRI, like pacemakers, are now routinely imaged. However, it is important for radiologists to be aware of new devices and attachments that do not appear on the standard questionnaires but still present the risk of adverse events, rather than simply wait for these events to accumulate before acting. Magnetic eyelashes can be purchased for less than \$20, so price should not be a significant barrier to use when considered with other beauty products.

We have shown that these magnetic eyelashes will significantly degrade clinical images but can also present a hazard to the patient. On that basis, they should be added to the preimaging MRI questionnaire, and clerical staff who schedule MRI scans should advise against their use on the day of scanning. MRI technologists should be aware of their existence and should question patients who appear to have unusually long eyelashes. All staff, including physicians and technologists with access to the scanner room, should avoid their use as well. Although we tested only one kind of magnetic eyelashes, it is reasonable to assume that all such lashes will behave in this manner, producing either somewhat less or somewhat more magnetic field distortion, and that all will be attracted to the static magnet.

A literature search did not reveal any reports of adverse events or imaging effects from magnetic eyelashes. However, it is possible that patients with these lashes have already undergone scanning, but the artifact

was sufficiently large that its source was uncertain. It is important to also consider that MRI accidents without substantial morbidity are likely underreported [3].

Conclusion

A new cosmetic product, magnetic eyelashes, should be of interest and should be a concern to radiologists and technologists working in the MRI environment. Using a phantom, we showed the substantial artifact caused by magnetic eyelashes, and detachment of one set of eyelashes from the phantom was noted on phantom movement within the scanner. Although friction and adhesion may differ from patient to patient, depending on the width and character of the native eyelashes of an individual, it is prudent to avoid imaging any patient with these eyelashes both because of the large artifact they create and because of their potential for detachment in the magnet bore. We strongly recommend adding a line about magnetic eyelashes to the MRI safety questionnaire and adding stops in the screening system to prevent entry of anyone with these eyelashes, including staff, into the MRI scanner room.

References

1. Weidman EK, Dean KE, Rivera W, Loftus ML, Stokes TW, Min RJ. MRI safety: a report of current practice and advancements in patient preparation and screening. *Clin Imaging* 2015; 39:935–937
2. Carter I. How magnetic lashes became the biggest thing in beauty. *Wall Street Journal* website. www.wsj.com/articles/how-magnetic-lashes-became-the-biggest-thing-in-beauty-11546613768. Updated January 4, 2019. Accessed June 3, 2019
3. Mansouri M, Aran S, Harvey HB, Shaqdan KW, Abujudeh HH. Rates of safety incident reporting in MRI in a large academic medical center. *J Magn Reson Imaging* 2016; 43:998–1007

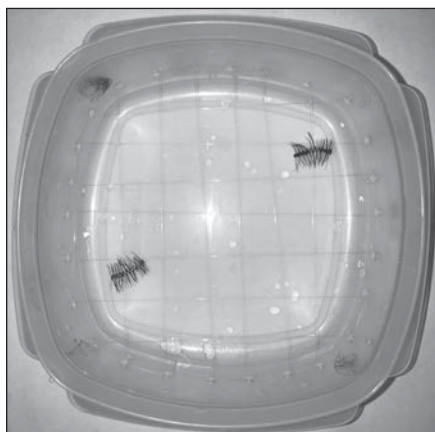


Fig. 1—Photograph shows magnetic eyelashes attached by single strings diagonally within container used as phantom to avoid merged artifact on imaging.

MRI Artifacts Created by Magnetic Eyelashes

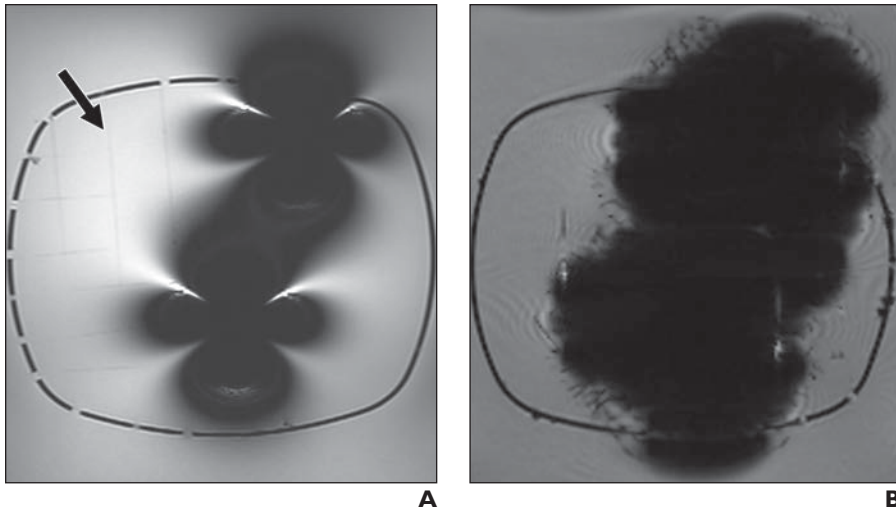


Fig. 2—Comparison of different MR images of phantom with magnetic lashes attached. **A**, T2-weighted sampling perfection with application-optimized contrasts using different flip-angle evolutions MR image shows nylon strings (*arrow*). **B**, Susceptibility-weighted image shows large artifact arising from magnetic eyelashes.

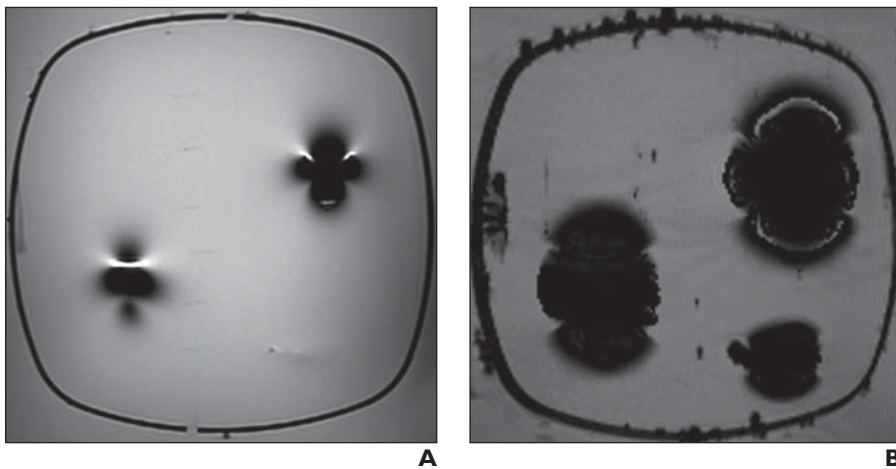


Fig. 3—MR images of same phantom seen in Figure 2 (which serves as relevant reference) but with three different aneurysm surgical clips attached. **A** and **B**, T2-weighted sampling perfection with application-optimized contrasts using different flip-angle evolutions MR image (**A**) and susceptibility-weighted image (**B**) show artifacts created by aneurysm clips that are similar to but much smaller than those created by magnetic lashes seen in Figure 2.