

RadioGraphics Index terms:
GENITOURINARY IMAGING
• Genital Tract, Male

Cumulative Index terms:
Penis; prostheses



THIS CONTRIBUTED MANUSCRIPT
WAS REVIEWED BY THE GENITOURI-
NARY IMAGING PANEL, AND AC-
CEPTED FOR PUBLICATION ON
MARCH 10, 1989.

From the Department of
Radiology, Columbia-Presby-
terian Medical Center, New
York, New York.

Address reprint requests
to D. M. Hovsepian, M.D., De-
partment of Radiology, Pres-
byterian Hospital, 622 West
168th Street, New York, NY
10032.

Penile prosthetic implants: A radiographic atlas

David M. Hovsepian, M.D.

Edward S. Amis, Jr., M.D.

Abstract: *This article provides an atlas of penile prosthetic implants currently in use. It is believed that an understanding of the structure and mechanism of these prostheses is essential to an accurate radiologic assessment of their integrity and to the recognition of the cause in cases of malfunction.*

Introduction

Since the 1940's, the treatment of male impotence has included a variety of surgical approaches. While the causes of impotence are many (1,4-6,8,13-17,20,21), the goal of treatment remains the same: to approximate as nearly as possible normal penile function. The last two decades have seen major advancements, particularly in the area of penile prosthetic implants. Currently, there are more than a dozen different types in use (Table I).

Table I
Penile Prosthetic Implants
(A wide variety is currently available.)

Semirigid	Inflatable
Solid Silicone	Distant Reservoir
Small-Carrion	AMS 700 (Scott)
Finney Flexi-Rod	AMS 700CX (Scott)
Finney Flexi-Rod II	Mentor "3-piece"
	Mentor GFS
Malleable	Uni-Flate 1000
Jonas	
AMS 600	Self-Contained
Mentor	Flexi-Flate
	Flexi-Flate II
Positionable	AMS Hydroflex
DuraPhase	
OmniPhase	

The earliest procedures used autologous bone or cartilage grafts to mimic erectile tissue, but these ideas were eventually abandoned because of poor long term results; namely, the grafts often became deformed or were resorbed (3). The history of the penile prosthesis since then has involved a series of advancements in two main areas: 1) the development of more durable and inert synthetic

materials, and 2) the mechanisms by which they are designed to function (3,7,8,11,13,15-17,20,21).

This article is intended to provide a useful atlas of those models which the physician is likely to encounter in practice. It is hoped that by understanding their architecture and mechanisms, one may be better able to evaluate their integrity radiographically.

Semirigid Penile Prostheses

The first synthetic prostheses employed acrylic materials and, later, silicone. These earliest attempts, the Lash-Loeffler and Pearman prostheses being the most commonly used of these devices, were troubled by migration, patient discomfort, and failure of the materials (3). Although a certain degree of success was achieved, the overall results were not entirely satisfactory.


Since then, a number of improvements in design and materials have produced a variety of semirigid implants which continue to enjoy widespread use, primarily because they are relatively inexpensive, reliable, and easy to implant when compared to the more sophisticated inflatable systems that will be discussed later (9). Often requiring only local or regional anesthesia, they are inserted after dilation of the

corpora cavernosa by saline or a mechanical dilator.

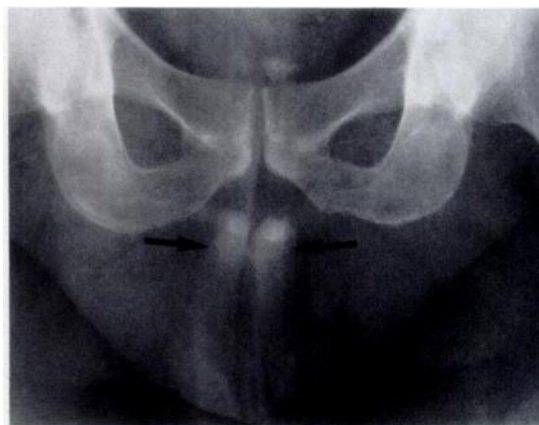SOLID SILICONE PROSTHESES

Small-Carrion (Mentor Corporation, Goleta, CA)

The first widely available prosthesis, the Small-Carrion, is a solid rod composed entirely of silicone (Figure 1). The penis, therefore, is maintained in a permanent state of tumescence. Despite this, patient satisfaction has been high, because it is relatively inexpensive and essentially trouble-free by virtue of its simplicity. By 1984, over 20,000 had been successfully implanted (3).



1A



1B

Figure 1
Small-Carrion prosthesis (A) Photograph of prosthesis (B) Radiograph The cylindrical implants are faintly visible in the corpora cavernosa (arrows). (Photograph courtesy of Mentor Corporation.)

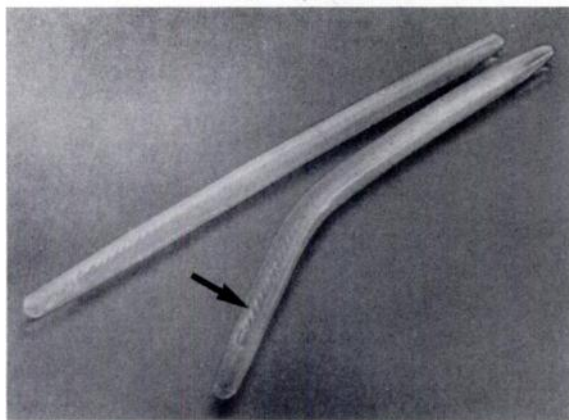
Finney Flexirod (Surgitek, Racine, WI)

The Finney Flexirod was developed to improve on the concealability of the Small-Carrion by providing a 5 cm segment of softer silicone elastomer at the base of the penis to serve as a hinge, allowing a flaccid mode (7). However, fracture of the rod occasionally occurred (1). Later, the silicone core was reinforced with dacron to create a firmer prosthesis, the Flexirod II.

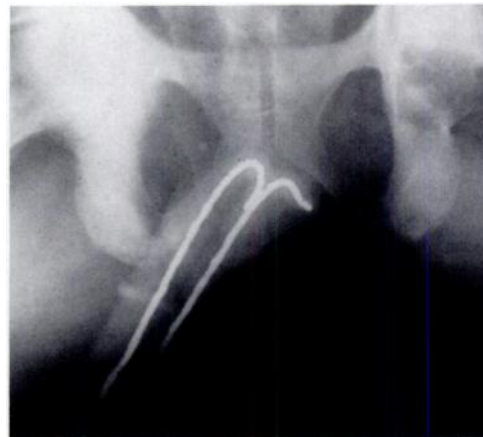
MALLEABLE PROSTHESES

ESKA Jonas (C. R. Bard, Covington, GA)

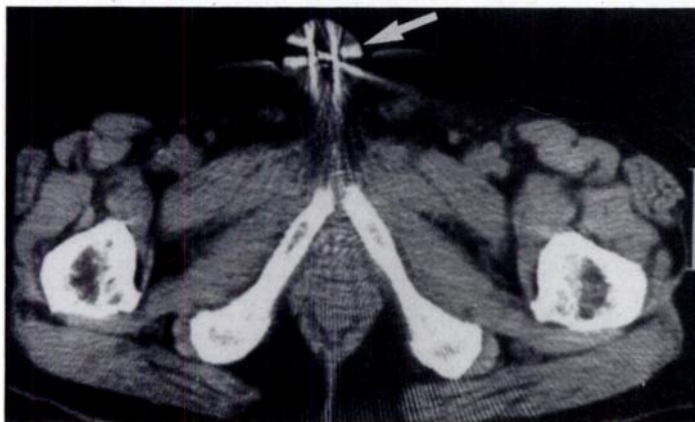
The Jonas Silicone-Silver malleable penile prosthesis (Figure 2) was devised to further improve concealability and satisfactory function, by adding a core of silver wire. Being malleable, it was also claimed that it simplified treatment in the case of Peyronie's disease; a corporoplasty was no longer needed to correct erectile deformities (15). This also holds true for other prostheses, including some inflatable models. Fracture of the wire core was reported with the early Jonas prosthesis (2,9,11,22). Each individual silver wire was therefore coated with Teflon, and the twisted strands recoated, with more successful results (9,10).



2A



2B



2C

Figure 2
ESKA Jonas malleable penile prosthesis (A) Photograph of prosthesis. Note the braided wire core (arrow). (B) Radiograph. The wire core is clearly evident inside the faintly visible silicone corporal implants. (C) CT section through the lower pelvis. Streak artifact is created by wire cores in the erect penis (arrow). (Photograph courtesy of C. R. Bard, Inc.)

AMS 600 (American Medical Systems, Minnetonka, MN)

The AMS 600 malleable prosthesis was introduced in 1983. It, too, utilizes a wire core, but stainless steel wire is used in place of silver and the core is reinforced with braided fabric and steel end-caps. A different type of silicone is also used, which is intended to improve malleability while retaining firmness. To date, no fracture of the wire core has been reported (9).

Mentor (Mentor Corporation)

Mentor, which produces the Small-Carrion prosthesis, also makes a malleable prosthesis that contains a stainless steel wire core (Figure 3). It differs in that the wire is coiled in a spiral, which is intended to reduce metal fatigue. Its reliability and functional characteristics have yet to be tested in clinical trials.

POSITIONABLE PROSTHESES

DuraPhase and OmniPhase (Dacomed, Minneapolis, MN)

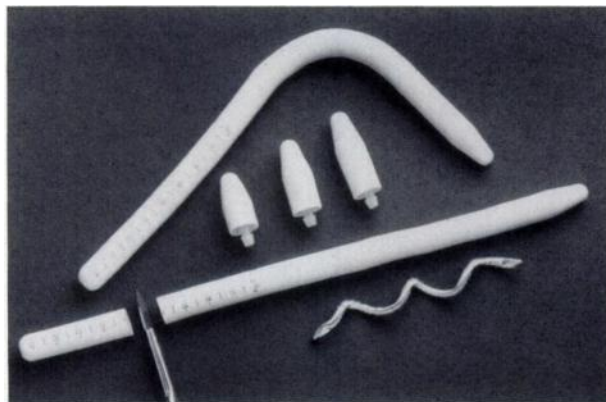
The newest prostheses to be introduced are the "positionable" DuraPhase and Omni-

Phase. Both have an outer coating of silicone elastomer, but differ from the previously described prostheses in the design of the core.

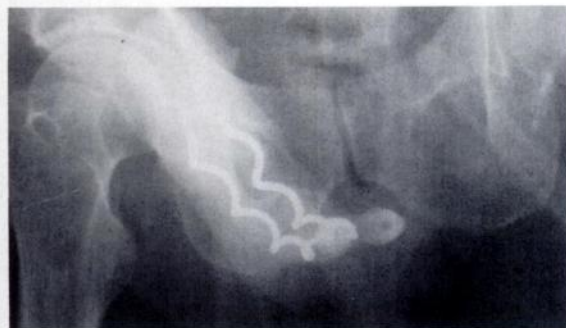The braided wire used in the malleable models has been replaced by a series of articulating plastic (polysulfone) segments. In the DuraPhase prosthesis, a central tensioning cable is connected at both ends to springs secured by metal housings. Like the malleable prostheses, it retains the position in which it has been placed.

The OmniPhase prosthesis utilizes essentially the same design, but has a mechanism which alters the length of the central cable (Figure 4). When activated, tension is placed on the cable and the prosthesis becomes positionable. When the mechanism is deactivated, the tension on the cable is relieved, and the prosthesis returns to flaccidity.

Fracture of the cable has been reported (12) and, unique to the OmniPhase prosthesis, an out-of-phase condition may occur, wherein one corporal cylinder becomes activated while the other remains deactivated. Provided that both units are functioning properly, the situation is readily correctable (18).

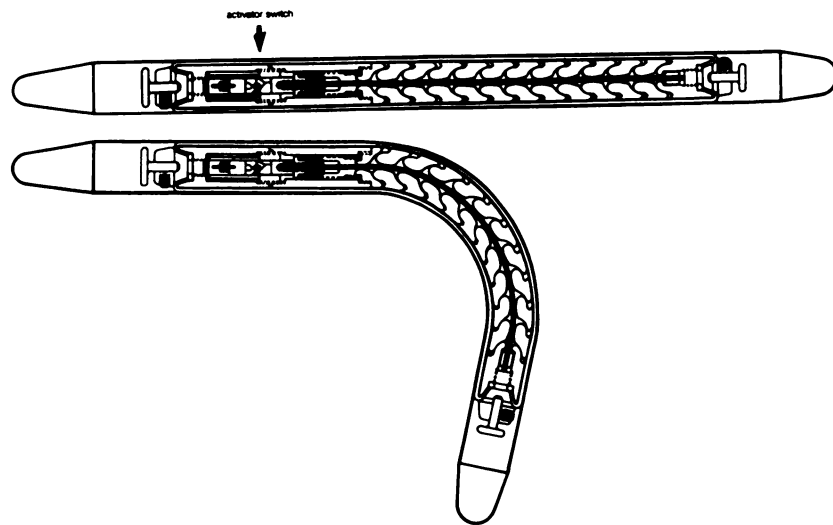


3A

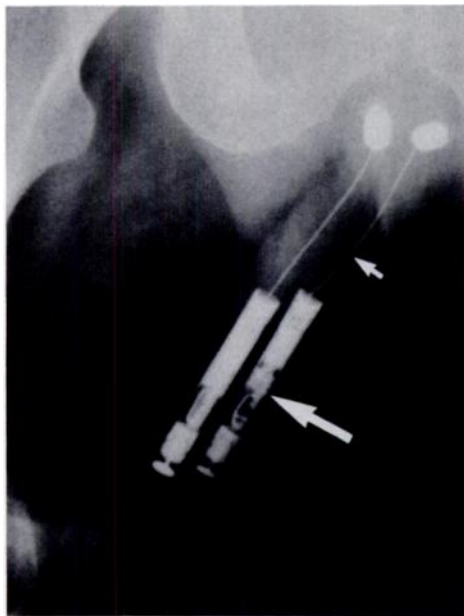


3B

Figure 3
Mentor malleable prosthesis (A) Photograph of prosthesis. Note the spiral wire core. (B) Radiograph. The prosthesis is characterized by its normal "corkscrew" appearance and dense proximal end-caps. (Photograph courtesy of Mentor Corporation. Radiograph courtesy of Dr. Richard L. Fein.)



4A



4B

Figure 4
OmniPhase prosthesis (A) Diagram of prosthesis Activator switch (arrow) (B) Radiograph Distal activator switch (large arrow) shortens tensioning cable (small arrow) to render previously flaccid prosthesis positionable. The articulating plastic segments which surround the wire are not visible. (Diagram and radiograph courtesy of Dacomed Corporation.)

Inflatable Penile Prostheses

The inflatable prostheses can be divided into two types: 1) self-contained and 2) distant reservoir systems. The essential mechanism of operation is the same: Fluid is pumped into distensible cylinders implanted in the corpora cavernosa. A series of valves regulates the flow in and out of the corporal implants. These de-

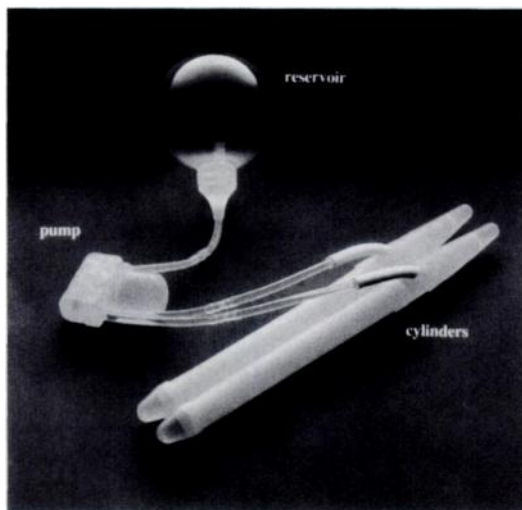
vices are more complex than the semirigid prostheses, and therefore have an additional set of problems which may arise. They are also considerably more expensive and difficult to implant. Nevertheless, they are quite popular because of their near-natural performance.

DISTANT RESERVOIR PROSTHESES

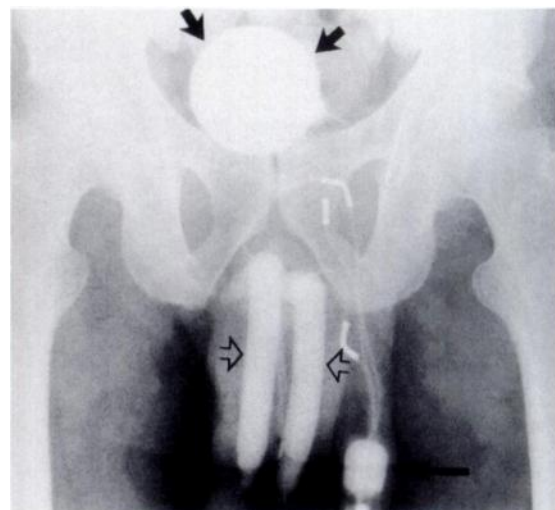
AMS 700 (American Medical Systems)

The first inflatable prosthesis was introduced in 1973 by Scott and co-workers (20). It consisted of a reservoir placed in the abdomen, two pumps implanted in the scrotum, and two inflatable corporal inserts. Early problems resulted primarily from failure of the materials (6,8,11,16). Developments to eliminate seams, prevent friction points, and create non-

kinkable tubing dramatically improved its success rate (8,9,11,16). The original design has continued to evolve, with the consolidation of the two pumps into a single unit. Often referred to as the "Scott" Inflatable Prosthesis, it is manufactured by American Medical systems as the AMS 500 (Figure 5). A more recent model, the AMS 700CX, has additional reinforcement of the corporal cylinders in order to reduce the incidence of leakage and aneurysmal dilatation (6).



5A



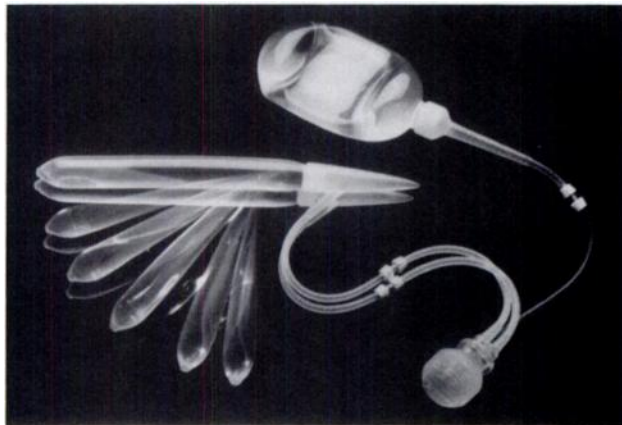
5B

Figure 5
AMS 700 (Scott) inflatable prosthesis (A) Photograph of prosthesis (B) Radiograph The abdominal reservoir (short arrows), scrotal pump (long arrow), and corporal implants (open arrows) are clearly demonstrated. The tubing and connectors are also easily seen. (Photograph courtesy of American Medical Systems.)

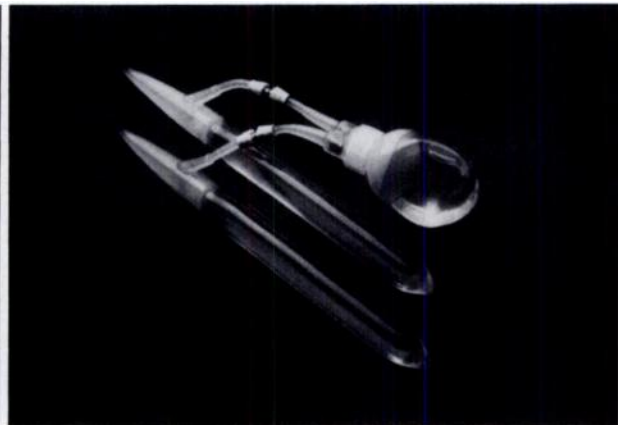Mentor Inflatable Prosthesis (Mentor)

In 1982, the Mentor corporation introduced a similar "3-piece" inflatable prosthesis (Figure 6). It consists of an abdominal reservoir, a scrotal pump, and inflatable corporal cylinders. It is constructed of a firmer material,

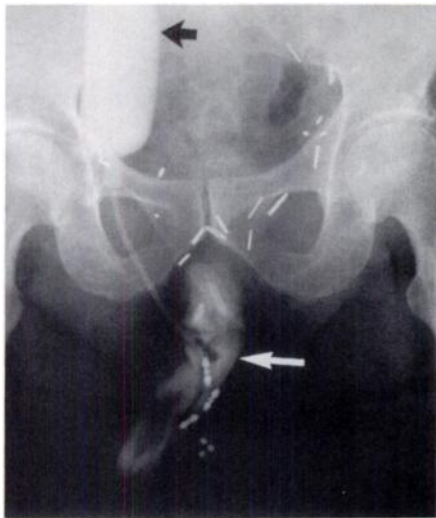called Bioflex polyurethane, in an effort to reduce the complications induced by the wear-and-tear of repeated inflation and deflation. Modifications have been made since its introduction, primarily in the tubing and connectors, but there have been no reports of leakage or aneurysm formation to date (4,5,13,14).



6A



7A

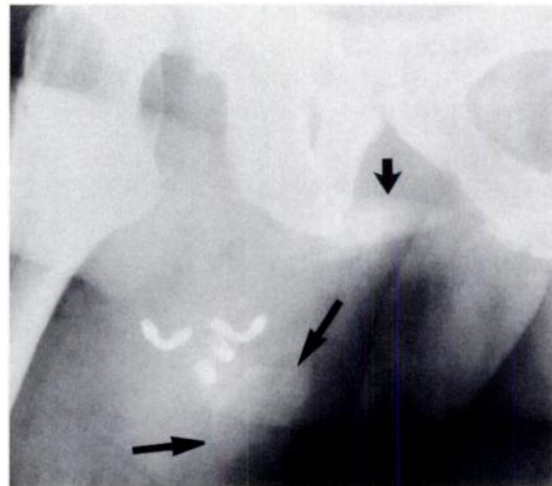


6B

Figure 6
Mentor inflatable prosthesis (A) Photograph of prosthesis (B) Radiograph. The abdominal reservoir (black arrow) is filled, while the corporal inserts (white arrow) are in the deflated state. The conical proximal ends of the corporal implants are clearly seen, as are the tubing and connectors, but the scrotal pump is visible only as three rounded opacities in the lower portion of the radiograph. (Photograph courtesy of Mentor Corporation. Radiograph courtesy of Dr. Richard L. Fein.)

Mentor GFS (Mentor)

The Mentor GFS eliminates the need for an abdominal operation, by consolidating the reservoir and pump into a single unit, the "Resi-pump", which is implanted in the scrotum



7B

Figure 7
Mentor GFS inflatable prosthesis (A) Photograph of prosthesis (B) Radiograph. The scrotal "Resi-pump" is faintly visible (long arrows). The cylindrical metal valves and curved tubing connectors are seen directly above. The conical crural tips of the corporal implants are also visible (short arrow). (Photograph courtesy of Mentor Corporation. Radiograph courtesy of Dr. Richard L. Fein.)

(Figure 7). This "2-piece" system, like the "3-piece" Mentor and AMS 700 prostheses, requires assembly in the operating room. The hydraulic fluid is usually sterile saline, which cannot be seen radiographically. One team has routinely used iohalamate meglumine (Con-

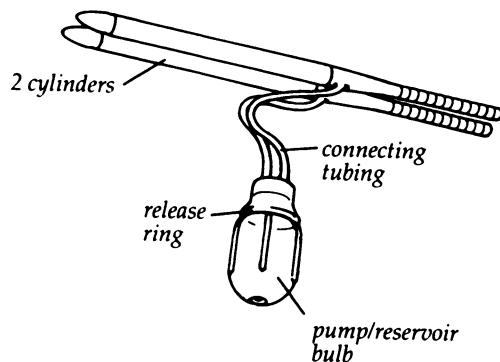
ray) mixed with saline without complication (5). Anecdotal reports of malfunction related to high-osmolarity contrast agents, however, have caused many to avoid this practice. This remains to be determined in clinical trial, and the newer low-osmolarity agents may avoid the problem altogether.

Uni-Flate 1000 (Surgitek)

The Uni-Flate 1000 prosthesis recently ended its clinical trial period with reportedly high success rates (19). Like the Mentor GFS, the pump and reservoir have been made into a single unit, which is implanted in the scrotum (Figure 8). Unlike the other inflatable prostheses, it is supplied as a pre-filled and pre-assembled system. The hydraulic fluid is non-radio-opaque sterile saline, however.

SELF-CONTAINED INFLATABLE PROSTHESES

Two self-contained inflatable prostheses are currently available. These devices are simi-



8A

Figure 8
Uni-Flate 1000 inflatable penile implant (A) Diagram of prosthesis (B) Radiograph. The combined reservoir-pump is clearly seen (large white arrows). The metallic spring in the release ring is part of the valve mechanism. The corporal cylinders are faintly visible (small white arrows) as are their denser corporal ends (black arrow). (Diagram courtesy of Surgitek. Radiograph courtesy of Dr. Thomas H. Stanisic.)

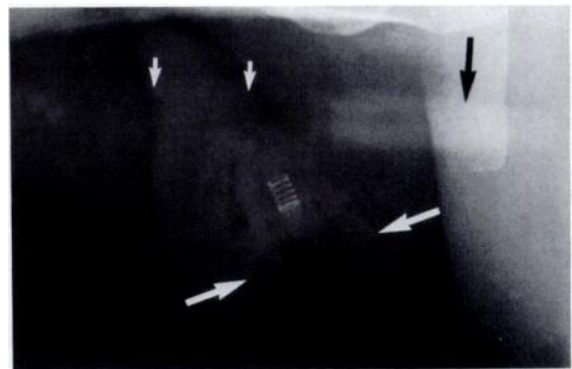
lar to the semirigid prostheses in that they consist only of corporal implants. Erection is achieved by transferring fluid from a reservoir chamber to an inflatable segment. They are also similar to the semirigid devices in that concealment can sometimes be difficult.

Hydroflex (American Medical Systems)

The Hydroflex self-contained penile prosthesis has a reservoir located in the proximal end of the prosthesis. Valves located distally control the flow in and out of the centrally located inflation chamber (Figure 9). As with other fluid-containing systems, leakage has been reported (17).

Flexi-Flate (Surgitek)

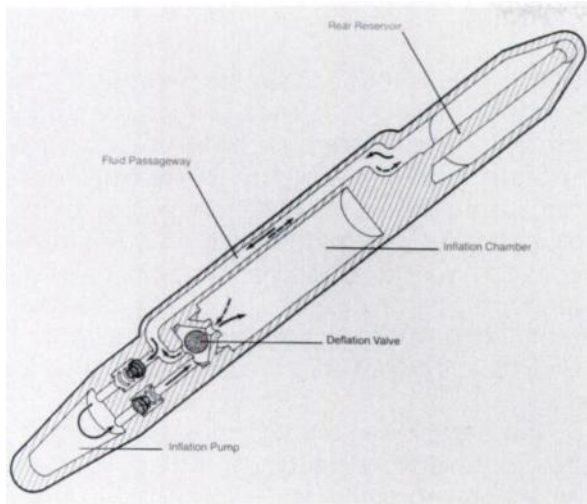
The Flexi-Flate penile implant is a coaxial system. A pump at the distal tip transfers the fluid from an outer reservoir chamber to an inflatable inner cylinder. Recently modified, the Flexi-Flate II is now available (Figure 10).



8B

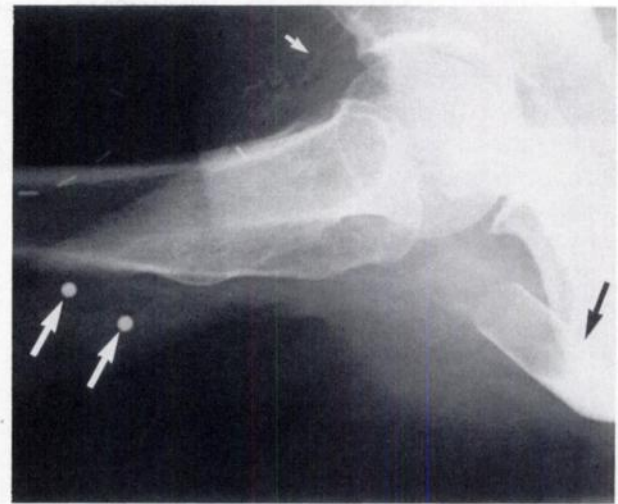Figure 10

Flexi-Flate inflatable penile implants (A) Diagram of Flexi-Flate and Flexi-Flate II prostheses (B) Radiograph. The proximal metal end caps are clearly seen (short arrows), while the corporal cylinders are only faintly evident (long arrows). (C) Radiograph. Using soft tissue technique, the distal pumps are now well demonstrated (arrow). (Diagram courtesy of Surgitek. Radiographs courtesy of Dr. Thomas H. Stanisic.)



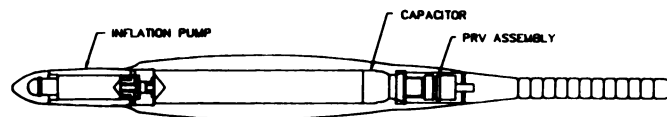
9A

Figure 9
AMS Hydroflex self-contained penile prosthesis (A) Diagram of prosthesis (B) Radiograph. Only the distal ball valves (large white arrows) and the proximal metal caps (black arrow) can be seen. Note calcifica-

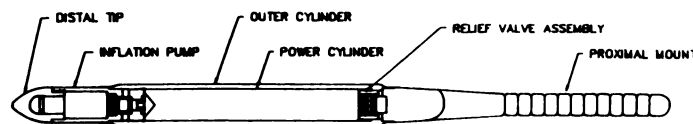


9B

tion in the pudendal arteries (small white arrow); diabetic vascular disease is a primary cause of male impotence. (Diagram courtesy of American Medical Systems. Radiograph courtesy of Dr. Thomas H. Stanisc.)

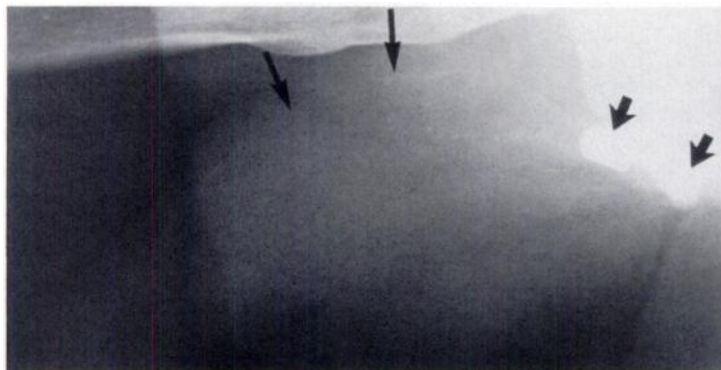


FLEXI-FLATE II

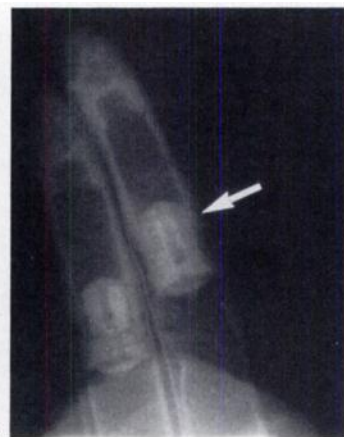

FLEXI-FLATE

10A



10B



10C

Radiographic Imaging

Evaluation of prosthetic implants should begin with AP and oblique radiographs which include the lower abdomen, pelvis, and scrotum. Soft-tissue technique is needed for optimal visualization and additional coned-down views may also be necessary. Care should be taken to insure that the whole system is included, especially in those models with abdominal reservoirs.

In evaluating the fluid-containing prostheses, only those that contain a contrast agent can be assessed for leakage. Tubing and connectors are often visible and should be fully scrutinized for kinks or discontinuity. With the self-contained and semirigid implants, one must be alert for fracture of the silicone, central wire core, or tensioning cable.

Migration of the corporal implants or ancillary components can occur when a friction

point develops that causes tissue erosion. It is therefore important to keep in mind the anticipated location of each segment of a prosthetic system. Patient discomfort, in the absence of infection, should alert the radiologist to the possibility that migration may occur. Any prosthetic device may become infected, necessitating removal (1,2,4,5,8,11,13,15,16). Often a rim of fibrosis remains that casts a radiographically visible silhouette of the prosthesis after its removal.

There are often enough clues for the astute diagnostician to suggest the cause of a malfunctioning prosthesis. Knowledge of the architecture and functional design of a prosthesis is the critical first step in achieving that end.

References

- Ahlberg B, Brattberg A, Norlen BJ. Eight years of clinical experience with inflatable and semirigid penile implants. *Scand J Urol Nephrol* 1986; 20:241-244.
- Benson RC, Patterson DE, Barrett DM. Long-term results with the Jonas malleable penile prosthesis. *J Urol* 1985; 134:899-901.
- Benson RC. Penile prostheses: Semirigid rod penile prostheses. *Semin Urol* 1984; 2:152-157.
- Brooks MB. 42 months of experience with the Mentor inflatable penile prosthesis. *J Urol* 1988; 139:48-49.
- Engel RM, Smolev JK, Hackler R. Experience with the Mentor inflatable penile prosthesis. *J Urol* 1986; 135:1181-1182.
- Fallon B, Rosenberg S, Culp DA. Long-term followup in patients with an inflatable penile prosthesis. *J Urol* 1984; 132:270-271.
- Finney RP. Finney flexirod prosthesis. *Urology* 1984; 23(5 Spec No.):79-82.
- Fishman IJ, Scott FB, Light JK. Experience with inflatable penile prosthesis. *Urology* 1984; 23(5 Spec No.):86-92.
- Gregory JG, Purcell MH. Penile prosthesis: Review of current models, mechanical reliability, and product cost. *Urology* 1987; 29:150-152.
- Jonas U. Letter to the Editor. *J Urol* 1985; 134:901.
- Kabalin JN, Kessler R. Five-year followup of the Scott inflatable penile prosthesis and comparison with semirigid penile prosthesis. *J Urol* 1988; 140:1428-1430.
- Krane RJ. Omniphase penile prosthesis. *Semin Urol* 1986; 4:247-251.
- Merrill DC. Clinical experience with the Mentor inflatable penile prosthesis in 301 patients. *J Urol* 1988; 140:1424-1427.
- Merrill DC, Javaheri P. Mentor inflatable penile prosthesis: Preliminary clinical results in 30 patients. *Urology* 1984; 23(5 Spec No.):72-74.
- Montague DK. Experience with Jonas malleable prosthesis. *Urology* 1984; 23(5 Spec No.):83-85.
- Mulcahy JJ. Use of CX cylinders in association with AMS 700 inflatable penile prosthesis. *J Urol* 1988; 140:1420-1421.
- Mulcahy JJ. The Hydroflex self-contained inflatable prosthesis: Experience in 100 patients. *J Urol* 1988; 140:1422-1423.
- Product literature. Dacomed, Minneapolis, Minn.
- Product literature. Surgitek, Racine, Wis.
- Scott FB, Bradley WE, Timm GW. Management of erectile impotence: Use of implantable inflatable prosthesis. *Urology* 1973; (2):80-82.
- Sidi AA, Koleilat N, Fraley EE. Evaluation and treatment of organic impotence. *Invest Radiol* 1988; 23:778-789.
- Tawil EA, Gregory JG. Failure of the Jonas prosthesis. *J Urol* 1986; 135:702-703.